Phil. Trans. R. Soc. Lond. B **300**, 493–511 (1983) [493]
Printed in Great Britain

THE CARDIAC INNERVATION OF *ELEDONE CIRRHOSA* (LAMARCK) (MOLLUSCA: CEPHALOPODA)

By P. J. S. SMITH† and P. R. BOYLE
University of Aberdeen, Department of Zoology, Tillydrone Avenue, Aberdeen AB9 2TN, U.K.

(*Communicated by V. C. Wynne-Edwards, F.R.S. – Received* 14 *June* 1982)

CONTENTS

The innervation to the cardiac organs and vessels of the octopods *Eledone cirrhosa*, *E. moschata* and *Octopus vulgaris* is described from vitally stained fresh material and wax-embedded sections. This innervation arises from the paired visceral nerves and includes two main peripheral ganglia (fusiform and cardiac) on each side.

Several new details of the innervation are reported. Nerves supplying the lateral venae cavae arise from the ventricular nerves at the level of the ventricle. Nerve fibres run to the efferent branchial vessels from the cardiac ganglia. A small ganglion, lying on the auriculo-ventricular nerve, is described for some specimens of both species of *Eledone*, and is named the auricular ganglion. Commissural strands linking the right and left ventricular nerves of either side are found in *Eledone*, comparable to those previously described from *Octopus*. The detailed branching pattern of the innervation shows considerable individual variation and consistent interspecific differences.

In *E. cirrhosa* the fine fibres innervating the inner and outer muscle layers of the auricle show distinct differences in their configuration. Innervation at the surface of the ventricular lumen and around the coronary arterial vessels shows evidence of

---

† Present address: A.R.C. Unit, Department of Zoolology, University of Cambridge, Downing Street, Cambridge CB2 3EJ, U.K.

specialization. The muscle of the branchial heart, particularly the valve leaflets at the junction of the heart and the lateral vena cava, is abundantly innervated.

The observations are discussed in relation to other cephalopods and to their probable physiological significance. It is suggested that they provide evidence for a greater degree of neural influence in the control of the cardiac organs than is usually supposed and that they support the idea that the lateral venae cavae have a significant role in the generation of circulatory pressures.

INTRODUCTION

The cardiac system of the dibranchiate cephalopods is composed of a number of contractile components. A single median ventricle receives blood through paired auricles in series with two laterally sited branchial hearts. In addition, some of the main connecting blood vessels are contractile. The complexity of this system, relative to other molluscs, is widely recognized although its detailed functioning is not well understood. The requirement for this multiplicity of component pumps is traditionally ascribed to the maintenance of relatively high blood pressure and flow rate through the gills, a feature of these large and active animals.

Blood returning from the body in the anterior vena cava is divided between the two lateral venae cavae and flows into the branchial hearts (figure 1). Venous blood also returns via the dorsal sinuses and the pallial veins. From the branchial hearts the blood leaves through the afferent branchial vessels and enters the vascular bed of the gill. Although it is usually assumed that the paired branchial hearts form accessory pumps to maintain blood flow through the gills, there is recent evidence (Smith 1982) to suggest that the contractions of the lateral venae cavae contribute significantly to the generation of the pressure wave. Blood is then drained from the gills through the efferent branchial vessels and into each auricle. The ventricle, filled via the auricles, forms the main cardiac pump supplying blood to the body through the dorsal, abdominal and gonadial aortae.

Observations made with *in vitro* preparations of *Eledone cirrhosa* and during *in vivo* studies on *Octopus vulgaris* have shown that the activity of the hearts and contractile vessels is coordinated (Smith 1979; Wells 1979, 1980). Several aspects of the coordinating role of the nervous system have been shown by these studies and a fuller account of the cardiac innervation is now required.

The innervation to the hearts of the Coleoidea has been studied by a number of authors (for a review see Young 1971). In the octopus this innervation arises from the pallioviscera1 and vasomotor lobes, both located at the posterior of the suboesophageal mass (Young 1971). Stimulation of this area, either mechanical or electrical, affects the veins and arteries of the arms (Mislin 1950). The fibre diameters within the visceral nerves, the nerves that innervate the cardiac organs, are described by Young (1967). The most detailed description of the innervation to any cephalopod heart is that given by Alexandrowicz (1960) in his study of *Sepia officinalis*. He recognized that distinct differences existed between the decapods and the octopods, and he pursued some of these with comparative studies on the cardiac ganglia (1963) and on the neurosecretory system of the anterior vena cava (1964, 1965). Both of these structures have physiological effects on cardiac performance (Wells 1980; Wells & Mangold 1980).

The complex nature of the circulatory system in the cephalopods suggests that, as in the vertebrates, some degree of reflex control might be expected. Wells (1980) has already proposed that the cardiac ganglia contribute to the regulation and the ventricle of other molluscs has been shown to provide an afferent return to the central ganglia (Kuwasawa *et al.* 1975;

S-Rozsa & Salanki 1973). An afferent input from the cardiovascular system of the octopus is presumed to run to the palliovisceral and vasomotor lobes of the brain (Young 1971). If the general parallels between the octopus and the vertebrates (Packard 1972) extend to the structural level, anatomical evidence of reflex sensory areas might be expected.

In this paper we examine the morphology and innervation of the various components of the cardiac system.

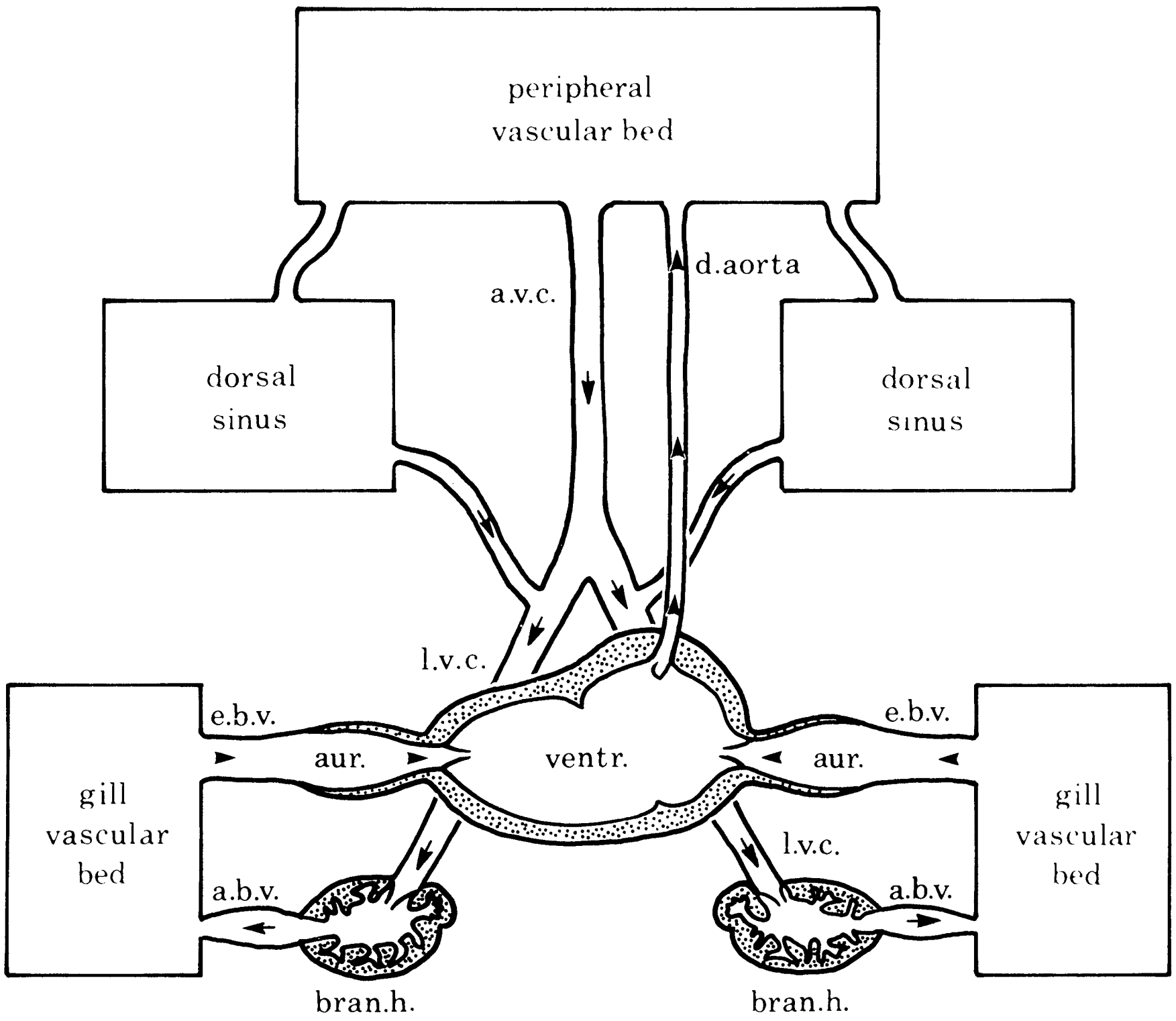

FIGURE 1. Diagram of the octopod circulatory system viewed from the dorsal surface. Direction of blood flow: ↑, deoyxgenated; ▲ , oxygenated.

MATERIALS AND METHODS

The study was based on the lesser or northern octopus, *Eledone cirrhosa* (Lam.) caught from the North Sea about 100 km off the port of Aberdeen. Comparative observations on *Eledone moschata* (Lam.) and *Octopus vulgaris* Cuvier were made at the Laboratorie Arago, Banyuls-sur-Mer, France.

The gross neuroanatomy of the cardiac organs was examined in freshly killed animals with the aid of methylene blue staining (Alexandrowicz 1960). The blue coloration of the tissue was found to be quite transient and so the preparations were drawn from direct observation as the dissection proceeded. Tissue to be used for histology was fixed in formalin (10 ml of 40% formaldehyde in 90 ml of seawater) buffered with magnesium carbonate and stored in the dark before being stained.

Details of organ innervation were investigated by means of a modification of Cajal's block silver impregnation technique as described by Stephens (1971). A further modification was added to suppress the staining of muscle and connective tissue, as well as to enhance the staining of nervous tissue. This involved processing through the Stephens method an additional piece of tissue, treated with trichloracetic acid (TCA), along with the tissue to be examined. A block of fixed mantle muscle (10 mm × 20 mm in area), treated for 1 h at 60 °C in TCA solution (5 g of TCA in 100 ml of buffered fixative) fulfilled this purpose. Unless otherwise stated this supplementary modification has been used throughout. Silver-impregnated tissue was embedded in paraffin wax, sectioned at 10 μm thickness and mounted in Styrolite (Raymond Lamb, London). Additional material was stained with Mallory's trichrome (Pantin 1964) and the histological preparations were photographed by means of a Leitz Orthoplan photomicroscope.

RESULTS

Gross neuroanatomy

Innervation to the cardiac organs of the octopus is derived solely from the right and left visceral nerves. These arise from the palliovisceral lobe of the suboesophageal portion of the brain and provide a pattern of innervation that is broadly bilaterally symmetrical. They run posteriorly from the brain over the ventral surface of the digestive gland, one on each side of the ventral septum. Branches are given off to the surrounding visceral organs.

Starting from the brain, the first peripheral ganglion encountered on each visceral nerve is the fusiform (first cardiac ganglion) at the level of the renal papilla. Nerves branching off at the level of the fusiform ganglion innervate the auricle, efferent branchial vessel, renal papilla and gonoduct of the respective side as well as the ventricle. Posterior to the fusiform ganglion, each visceral nerve turns dorsolaterally towards the branchial heart and enters the cardiac ganglion (second cardiac ganglion) located there (figure 5). Side branching of fine nerves occurs at this ganglion to supply the branchial heart, efferent branchial vessel, branchial heart appendage and the lateral extremity of the lateral vena cava. Distal to the cardiac ganglion the main nerve trunk, now called the branchial connective, runs anteriorly and laterally over the ventral surface of the branchial heart towards the gill. At the base of the gill it enters the string of branchial ganglia running on the visceral side of the afferent branchial vessel. During our study no detailed observations on the branchial ganglia have been made which can add to the published literature (Alexandrowicz 1960; Young 1967).

The main propulsive elements of the octopod circulatory system receive their innervation from the visceral nerves at the level of the fusiform and cardiac ganglia. The pattern of nervous supply shows inter- and intra-specific differences.

In *E. cirrhosa* several small nerve bundles leave the fusiform ganglion and innervate the renal sac membrane, the renal papilla, auricle and gonoduct (figure 2*b*, 1–3). There is some individual variation in that they emerge either from the body of the ganglion or from the main nerves distal to it. The ventricle is innervated mainly by the ventricular nerve (figure 2*b*, 4) which arises from the visceral nerve immediately distal to the fusiform ganglion in all specimens of *E. cirrhosa* examined. In several specimens of *E. cirrhosa* another small ganglion was present on the ventricular nerve; it may be named the auricular ganglion (figure 2*c*) and will be discussed later in more detail. From the fusiform ganglion fine nerve bundles emerge to innervate the auricle but their precise arrangement shows considerable variation between individuals. The main nerve supply to the auricle is from the auricular nerve which arises from the body of the fusiform ganglion (figure 2*b*, 5). The auricular nerve is frequently compounded with the ventricular nerve, although the degree of association varies considerably between individuals and between the left and right sides of the same animal.

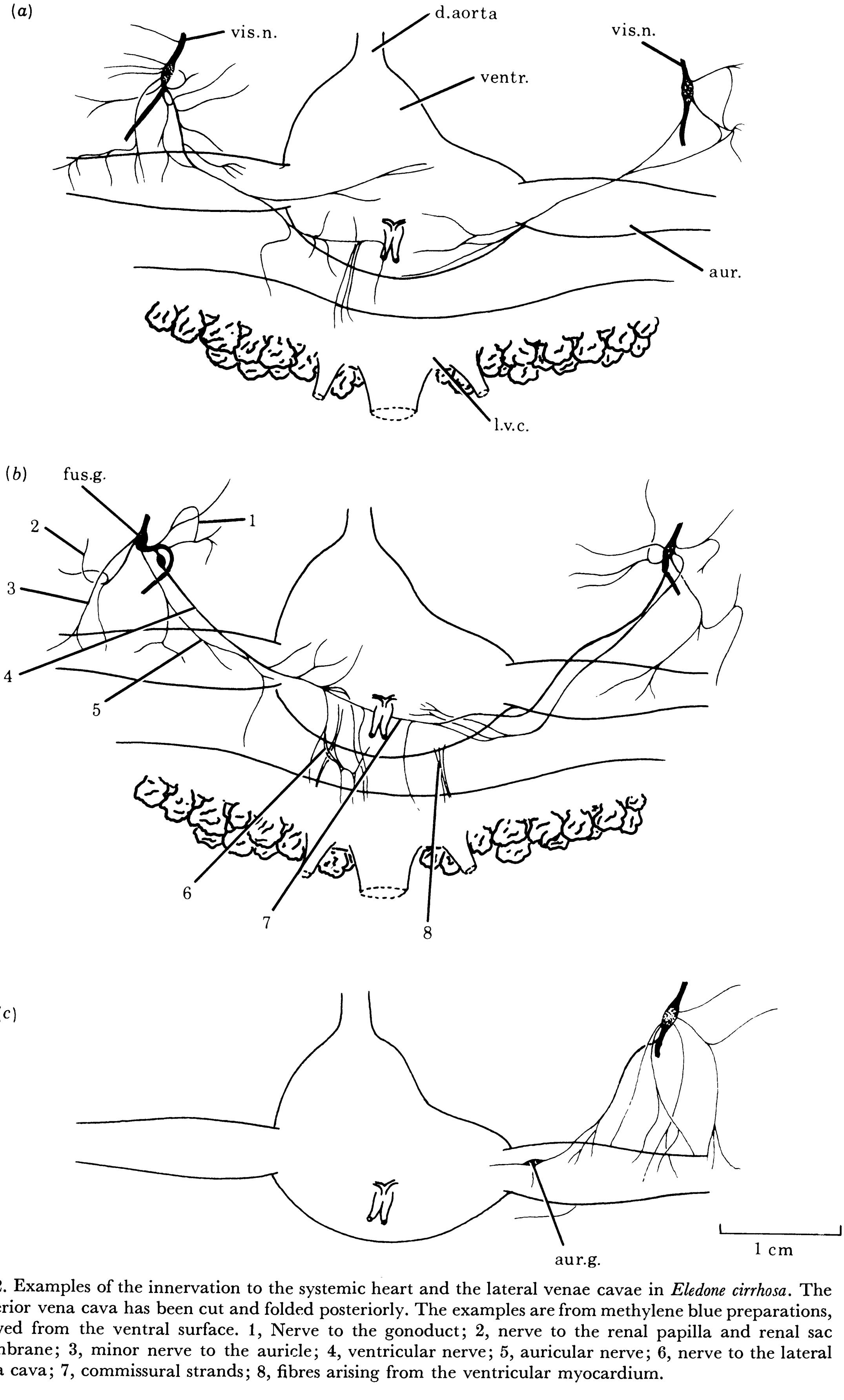

FIGURE 2. Examples of the innervation to the systemic heart and the lateral venae cavae in *Eledone cirrhosa*. The anterior vena cava has been cut and folded posteriorly. The examples are from methylene blue preparations, viewed from the ventral surface. 1, Nerve to the gonoduct; 2, nerve to the renal papilla and renal sac membrane; 3, minor nerve to the auricle; 4, ventricular nerve; 5, auricular nerve; 6, nerve to the lateral vena cava; 7, commissural strands; 8, fibres arising from the ventricular myocardium.

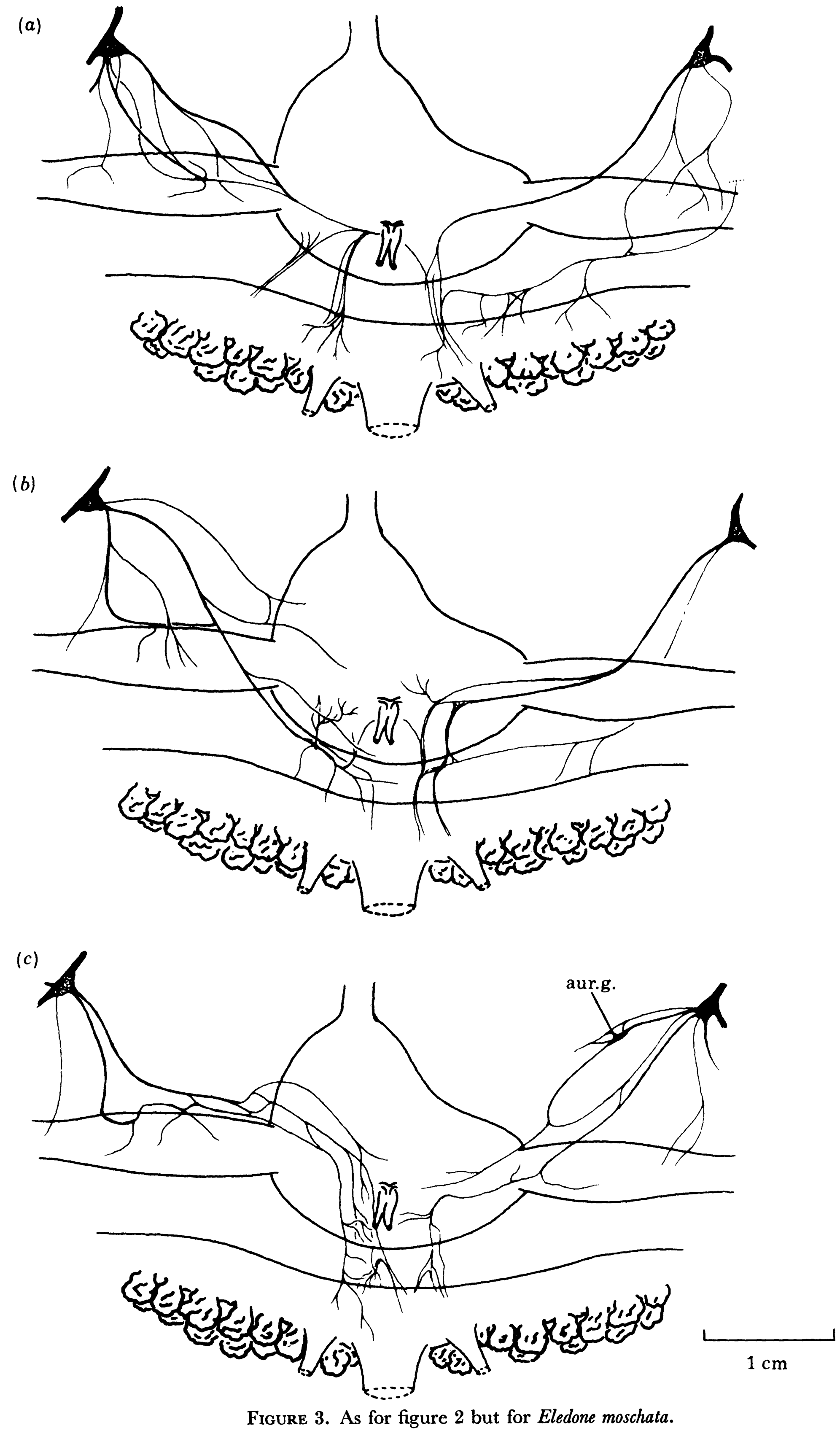

FIGURE 3. As for figure 2 but for *Eledone moschata*.

The branching of nerves over the ventral surface of the ventricle is difficult to follow because the ventricular muscle fibres also take up methylene blue. The extent of the innervation to the ventricle surface shown in figure 2 is likely to have been underestimated by the omission of finer branches. The nerve fibres found running over the ventricle are predominantly on the ventral surface and close to the equator. Nerve bundles from the left and right ventricular nerves form one or more commissural strands posterior to the abdominal aorta (figure 2*b*, 7).

The innervation of the anterior region of the lateral venae cavae is derived from the same nerve bundles that supply the auricle and ventricle. This innervation comprises numerous small nerve bundles arising from the ventral surface of the ventricle (figure 2*b*, 6) which run through the connective tissue layer between the ventricle and lateral venae cavae. Frequently, they run parallel to sinuses draining the coronary venous supply into the lateral venae cavae. Fine fibres similar to those described above are also seen to run between these two structures (figure 2*b*, 8) but we could not assign them to any of the identified nerve bundles.

The nerves from the fusiform ganglia in *E. moschata* (figure 3) show considerable similarity to those of *E. cirrhosa*, though there are certain specific differences. As in *E. cirrhosa* the innervation to the auricle and ventricle is derived from initially separate auricular and ventricular nerves. In *E. moschata*, however, the ventricular nerve arises from the body of the fusiform ganglion, rather than as a branch of the distal portion of the visceral nerve.

When compared with *Eledone*, the pattern of innervation in *O. vulgaris* appears simpler, with fewer detectable fine nerves to the lateral venae cavae, in spite of our use of similar anatomical methods to explore them (figure 4). The auricular and ventricular nerves arise from the body of the fusiform ganglion, as in *E. moschata*, but they usually run together as a single bundle for the greater part of their length. In *O. vulgaris* the commissural strand, linking the left and right ventricular nerves, more often runs anterior to the abdominal aorta and its diameter is, in proportion greater than in either species of *Eledone*.

The cardiac ganglia in the three species (figure 5) are located on the ventral surface of the branchial hearts partly overlying the pallial veins. From each cardiac ganglion a number of small nerve bundles innervate the surrounding tissue. The strong pigmentation of the branchial heart, however, hinders the tracing of the finest nerve bundles. In *E. cirrhosa* and *E. moschata* the pattern is closely similar (figure 5*a–e*), often with the largest bundle running to the ventral surface of the branchial heart itself (figure 5*c*, 1). A number of smaller nerve bundles innervate the pallial vein and valve region of the lateral vena cava (figure 5*c*, 2). The branchial heart appendage, the base of the lateral vena cava and the heart valve leaflets (sited at the junction between the lateral vena cava and branchial heart), are also innervated from the cardiac ganglion. In both *E. cirrhosa* and *E. moschata*, one or two nerve bundles leave the ventral surface of the ganglion and run through the renal sac membrane to innervate the efferent branchial vessel (figure 5*c*, 3). Only one *Octopus* was examined in any detail for comparison, and the presence of a nerve branch to the efferent branchial vessel, corresponding to that in *Eledone*, was not confirmed (figure 5*f*).

The results of this section are summarized in figure 6 and table 1.

Peripheral ganglia

The major ganglia associated with the cardiac organs and gills of the octopods have been described in the published literature (for a review see Young 1971) and will therefore be dealt with only briefly. This section concentrates on the description of an auricular ganglion, whose presence is hitherto unreported in the Octopoda.

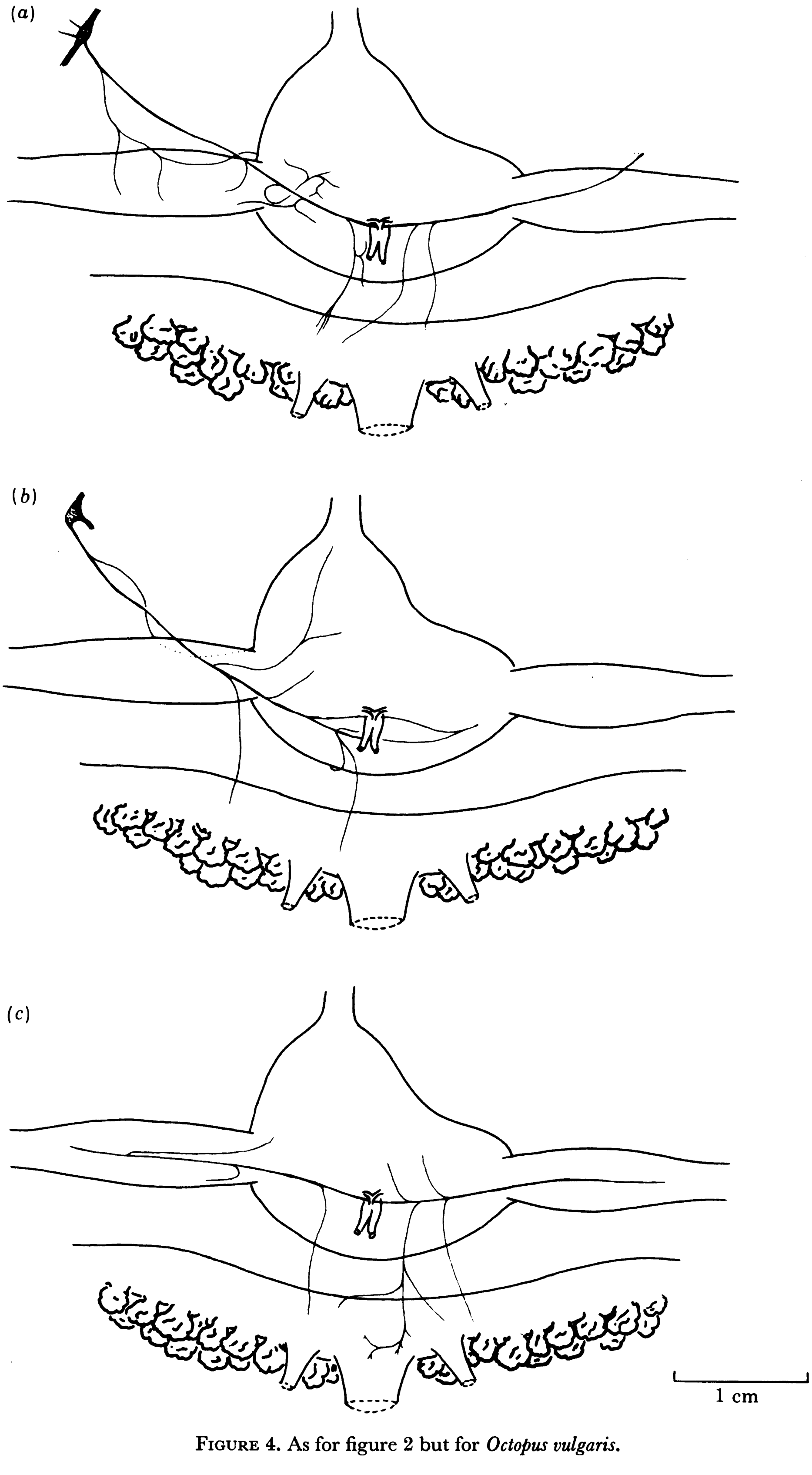

FIGURE 4. As for figure 2 but for *Octopus vulgaris*.

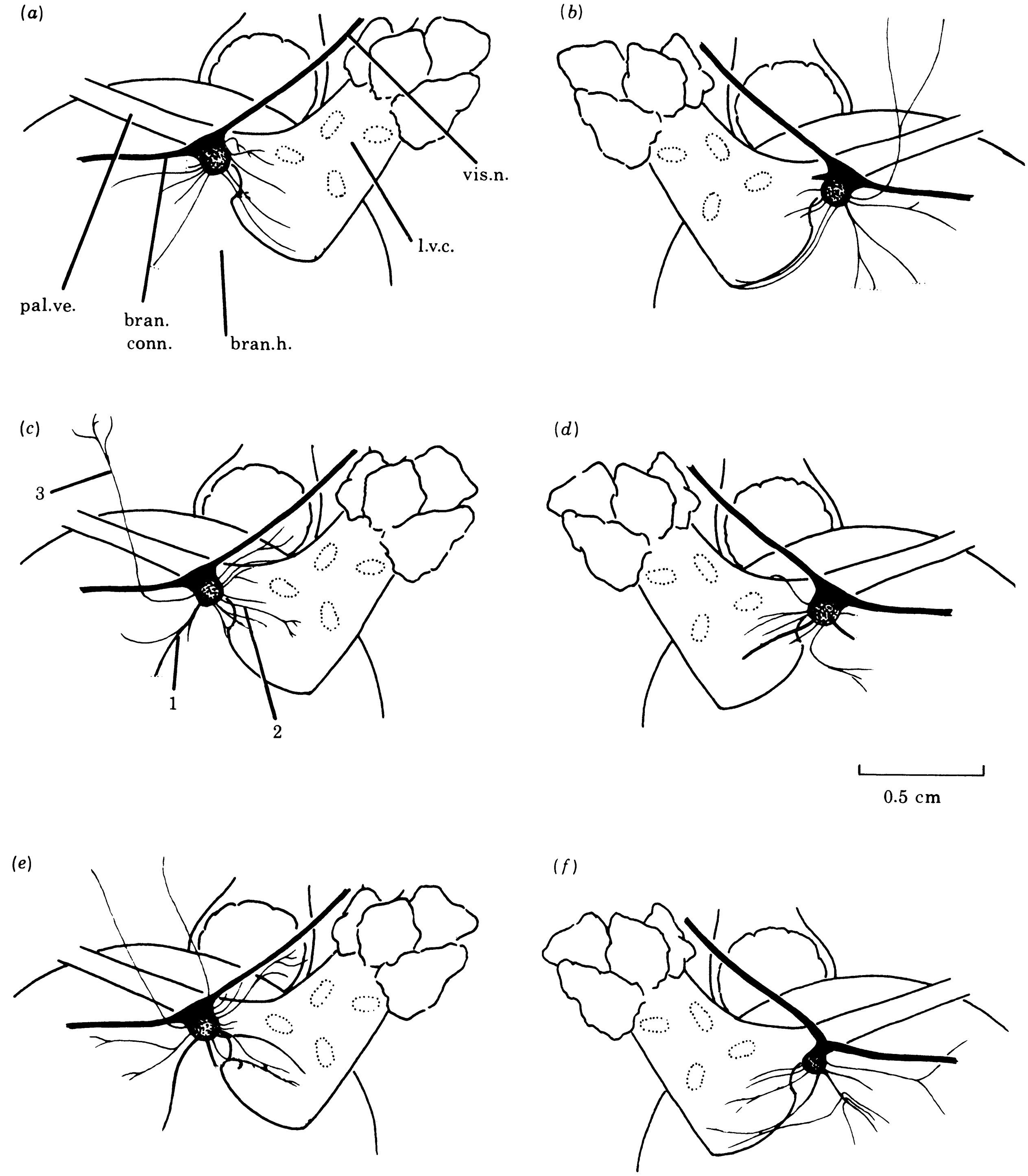

Figure 5. Examples of the innervation to the branchial heart in the three species of octopod studied ((*a*, *b*) *Eledone cirrhosa*, (*c–e*) *Eledone moschata*, (*f*) *Octopus vulgaris*). Examples of both left and right hearts are illustrated. The drawings were made from methylene blue preparations. 1, Nerve to the branchial heart; 2, nerves to the base of the lateral vena cava and pallial vein; 3, nerve to the efferent branchial vessel.

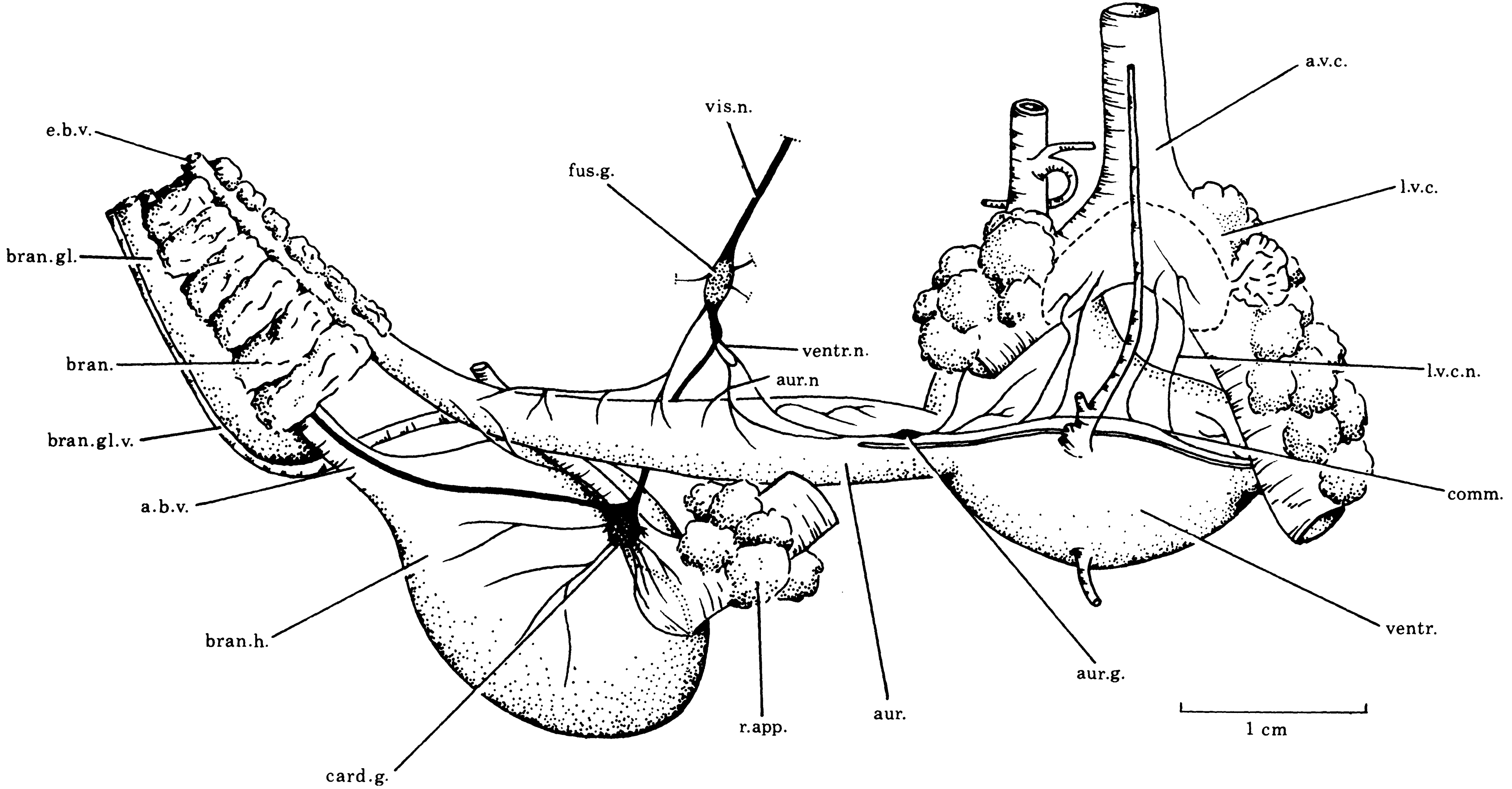

FIGURE 6. Summary of the innervation to the hearts and associated vessels in *Eledone cirrhosa*. The preparation is viewed from the ventral surface and is simplified. Only the innervation to the right side is shown, but, with the exception of the auricular ganglion, the overall pattern is symmetrical. The nerves to the gonoduct and renal papilla are omitted, as are sections of the lateral vena cava and gill. (Modified from Smith (1981.))

TABLE 1. SUMMARY OF THE INNERVATION TO THE HEARTS AND ASSOCIATED VESSELS IN THE THREE SPECIES OF OCTOPODS STUDIED

(Abbreviations: g., ganglion; n., nerve.)

<table>
<tr><th>site</th><th><i>E. cirrhosa</i></th><th><i>E. moschata</i></th><th><i>O. vulgaris</i></th></tr>
<tr><td rowspan="2">ventricle</td><td>(<i>a</i>) ventricular n. arising immediately distal to fusiform g.</td><td>(<i>a</i>) ventricular n. arising directly from fusiform g.</td><td rowspan="2">(<i>a</i>, <i>b</i>) ventricular n. arising directly from fusiform g. proximally compounded with auricular n.</td></tr>
<tr><td colspan="2">(<i>b</i>) auricular n. arising from fusiform g.
(<i>c</i>) auricular g., if present, lying on ventricular n.</td></tr>
<tr><td>auricle</td><td colspan="2">(<i>a</i>) auricular n. arising directly from fusiform g.
(<i>b</i>) occasional fine branches from ventricular n.
(<i>c</i>) minor nerves arising variably from fusiform g.</td><td>(<i>a</i>, <i>b</i>) auricular n. arising directly from fusiform g. proximally compounded with ventricular n.</td></tr>
<tr><td>efferent branchial vessel</td><td colspan="2">(<i>a</i>) extensions of minor nerves to auricle
(<i>b</i>) nerves arising directly from cardiac g.</td><td>(<i>a</i>) innervation not observed.</td></tr>
<tr><td>branchial heart</td><td colspan="3">(<i>a</i>) nerves arising directly from cardiac g.</td></tr>
<tr><td>lateral vena cava</td><td colspan="2">(<i>a</i>) branches of ventricular n. especially at level of ventricle
(<i>b</i>) occasional branches of auricular n.
(<i>c</i>) nerves from cardiac ganglion to base of lateral vena cava</td><td>(<i>a</i>) same, but fewer, thicker nerves</td></tr>
</table>

The two fusiform ganglia, located symmetrically on the right and left visceral nerves, lie on the ventral surface of the renal sacs within the perivisceral membrane. In each ganglion, an outer rind of nerve cells surrounds the central neuropil. The majority of the nerve fibres in the visceral nerve pass through the fusiform ganglion uninterrupted, and only a small proportion deviate into the neuropil. The auricle, lateral vena cava and the ventricle receive innervation from the branches emerging at the level of the fusiform ganglion. We cannot say what proportions of the nerve fibres in this supply arise from cell bodies located in the ganglion, or alternatively as continuous fibres from the visceral nerve. In *E. cirrhosa* fibres in the ventricular nerve have been observed running towards both the fusiform and the cardiac ganglia.

The small auricular ganglion already mentioned is located on the ventricular nerve. In *E. cirrhosa* it shows individual variation both in its occurrence and relative position. Of the 20 female animals closely examined, the ganglion was identified in five, but in none of these was it found on the ventricular nerve of both sides; bilateral symmetry thus commonly appears to be lacking. In four specimens the ganglion was within the connective tissue layer of the auricle close to the junction with the ventricle (see figure 2*c*). The presence of nerve cells within the ganglion was confirmed by histological examination. In a fifth preparation the ganglion was on the ventricular nerve just beyond its divergence from the distal portion of the visceral nerve (figure 2*b*). Light microscope examination confirmed its cellular nature and independence from the fusiform ganglion.

Serial sections through an auricular ganglion (figure 7*a–c*, plate 1) show its structure to be organized in a typically cephalopod manner (Young 1972). Nerve cell bodies surround a central neuropil and a proportion of the ventricular nerve fibres appear to pass through the ganglion without deviation. The auricular ganglion illustrated is approximately 250 μm long and contains in the region of 280 cell bodies.

Description of plate 1

Figure 7. Examples of serial sections through the auricular ganglion. Note the presence of nerve cell bodies, fibre tracts and neuropil. These sections were stained with Cajal's stain, as modified by Stephens (1971).

Figure 8. Nerve cell bodies located in the visceral nerve immediately distal to the fusiform ganglion.

Figure 9. A higher-power view of the cells illustrated in figure 8, confirming their cellular nature.

Figure 10. Nerve cell bodies in the branchial connective at the junction of the branchial heart and the afferent branchial vessel.

Figure 11. A higher-power view of the region of cell bodies shown in figure 10. An area of possible neuropil is evident.

Description of plate 2

Figure 12. A large nerve bundle running within the ventricular myocardium.

Figure 13. A single nerve fibre within the ventricular myocardium. The fibre tracks along the muscle fibres and shows varicosities along its length.

Figures 14 and 15. Serial sections through a branch of a coronary artery, showing an abundant innervation arising from a small nerve bundle.

Figure 16. A higher magnification of the innervation to the coronary artery illustrated in the previous figures. The innervation is both extensive and complex.

Figure 17. A site of abundant innervation in the ventricular myocardium. There is a plexus of fibres in the muscle bordering the lumen. The section was cut in the region of the auriculo-ventricular valve.

Figure 18. Serial sections cut through putative nerve cell bodies located at the border of the ventricular myocardium and the epicardial layer. The cell bodies are closely associated with a bundle of nerve fibres which remain within the myocardium.

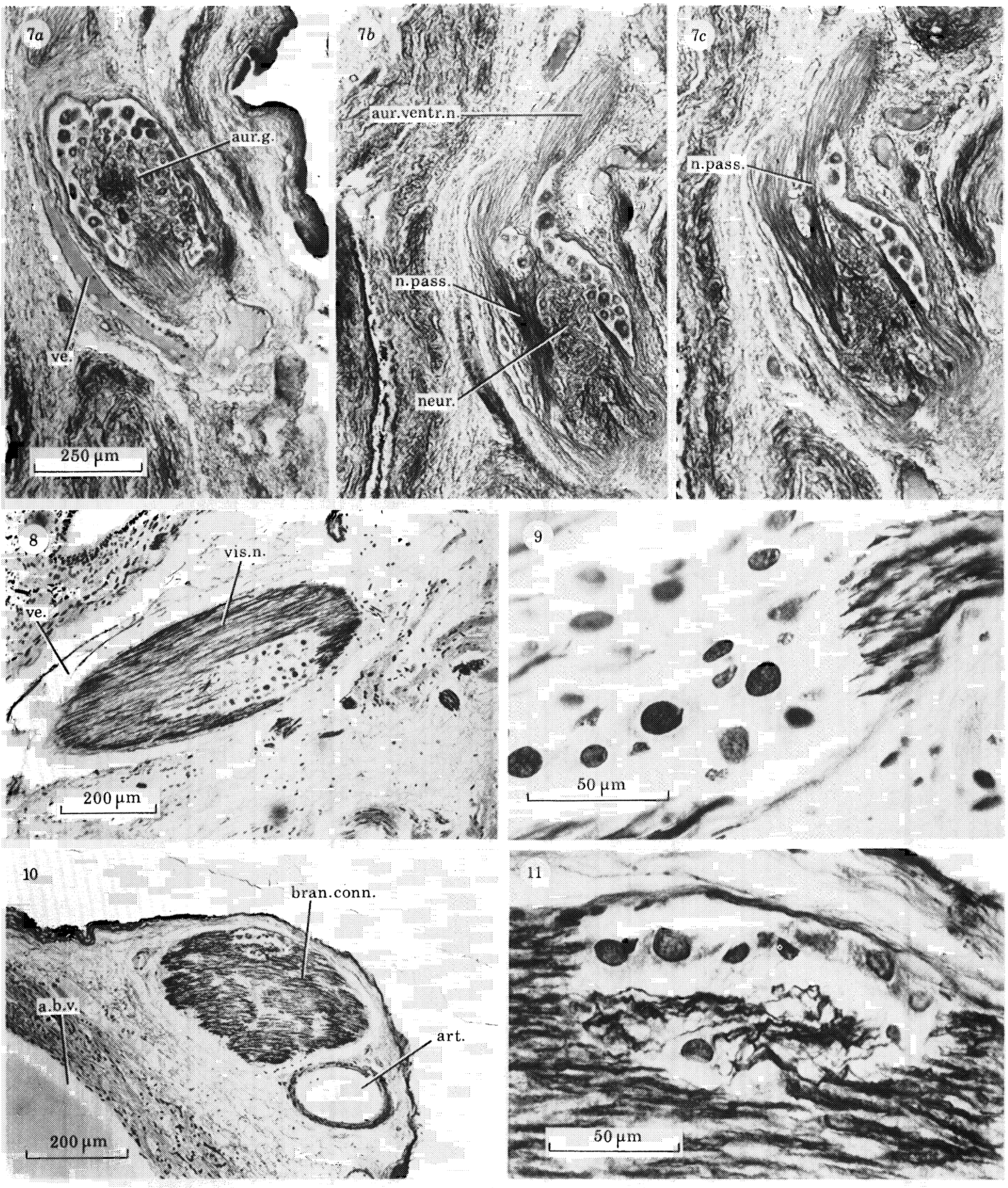

FIGURES 7–11. For description see opposite.

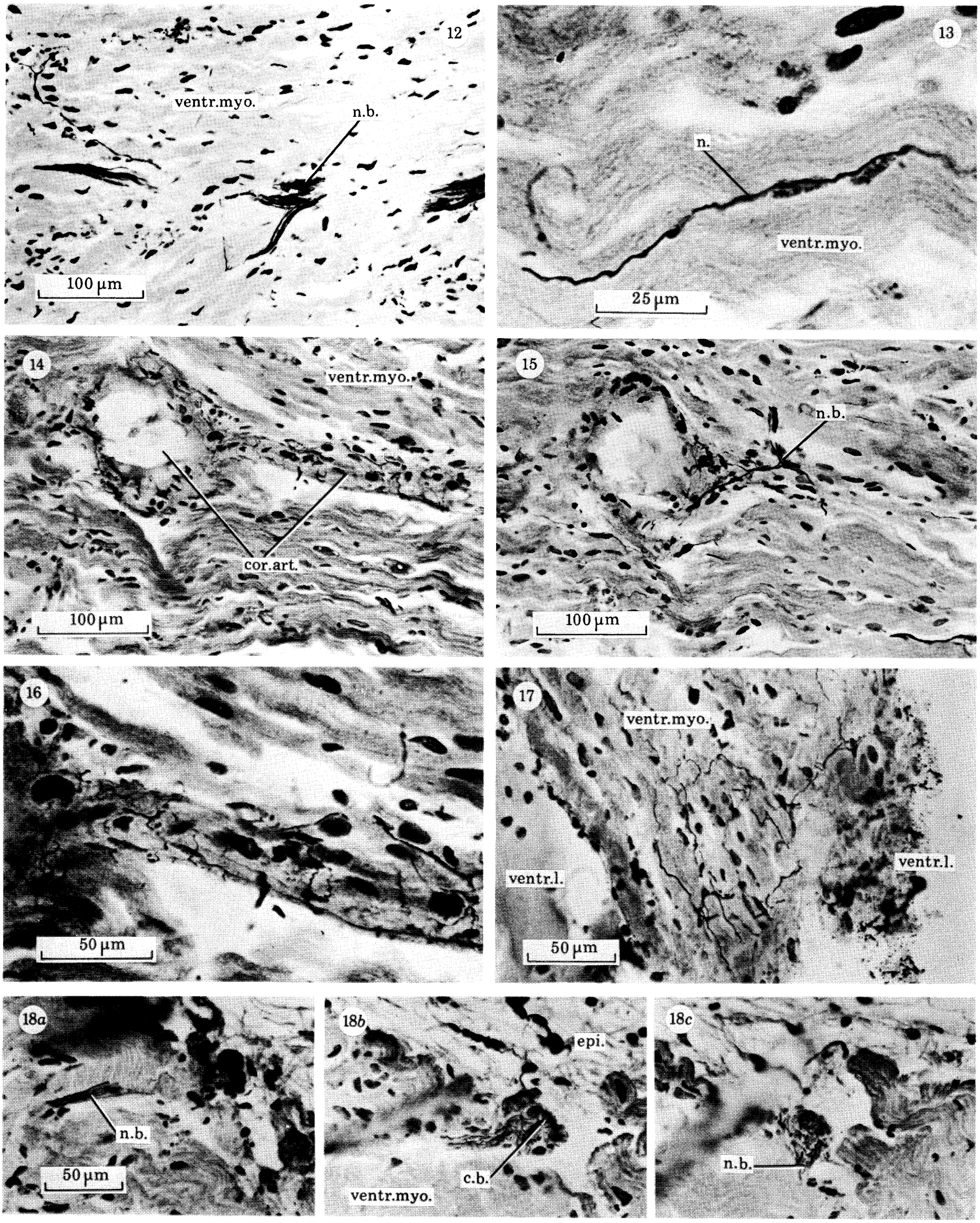

FIGURES 12–18. For description see page 504.

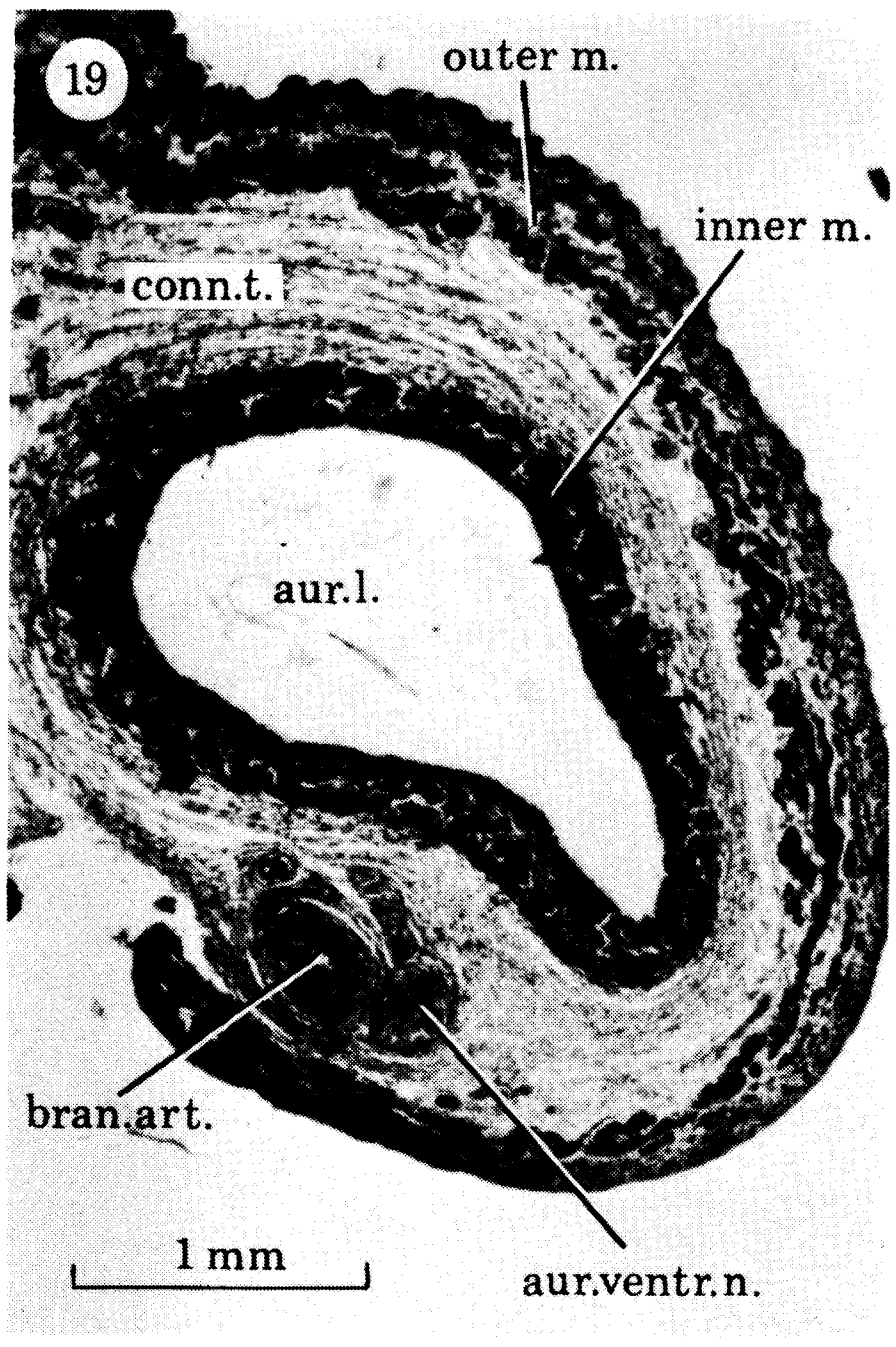

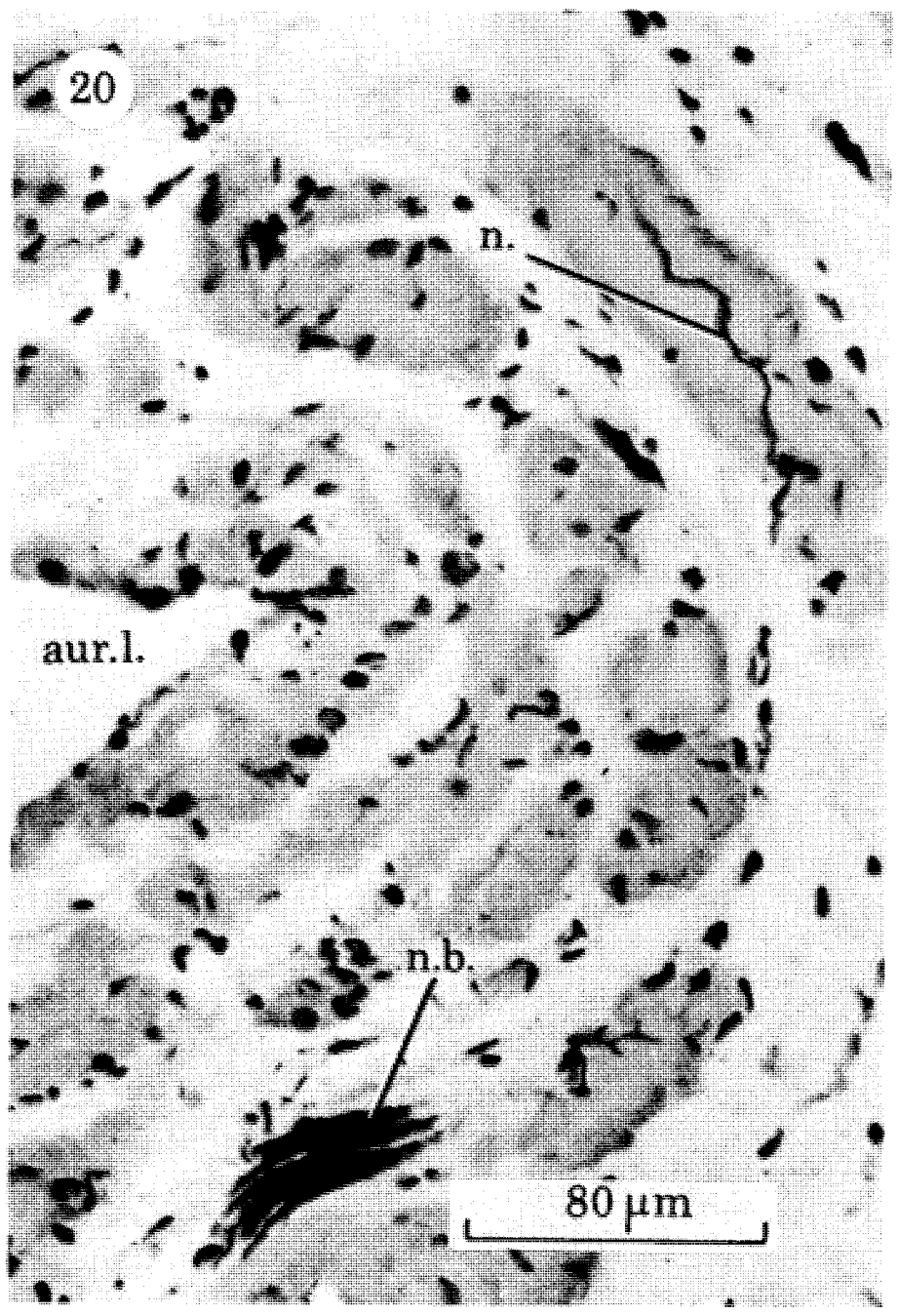

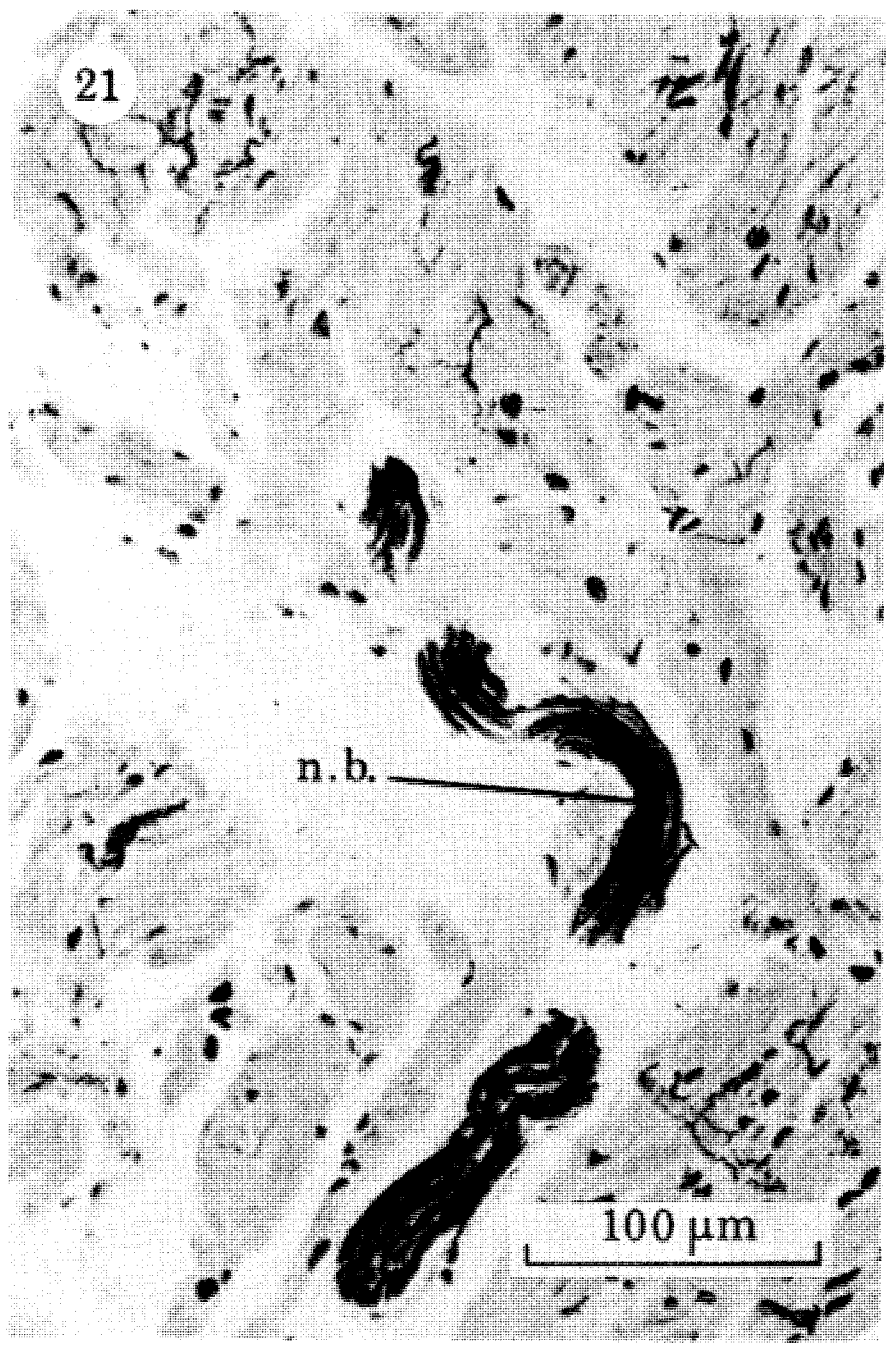

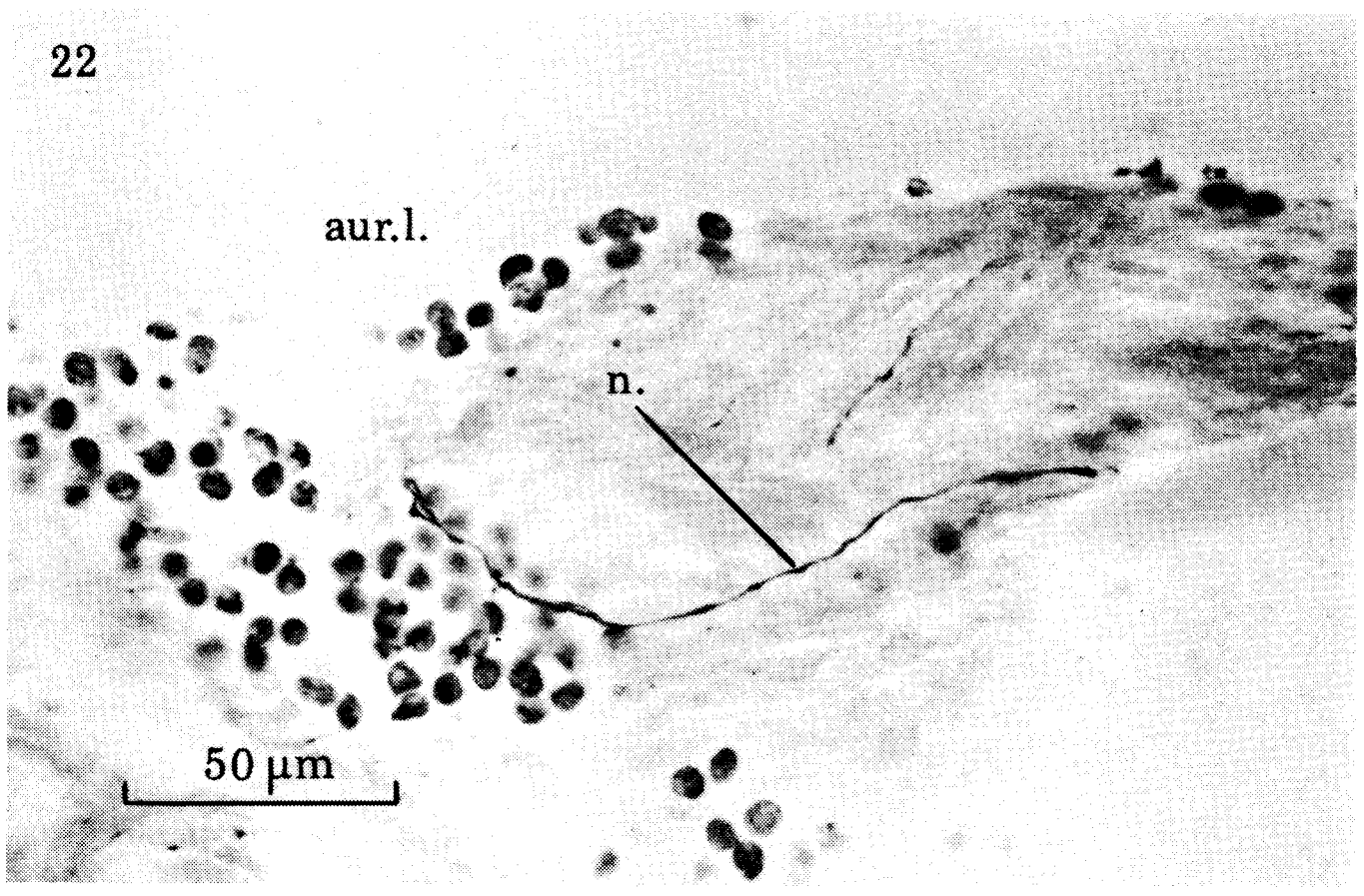

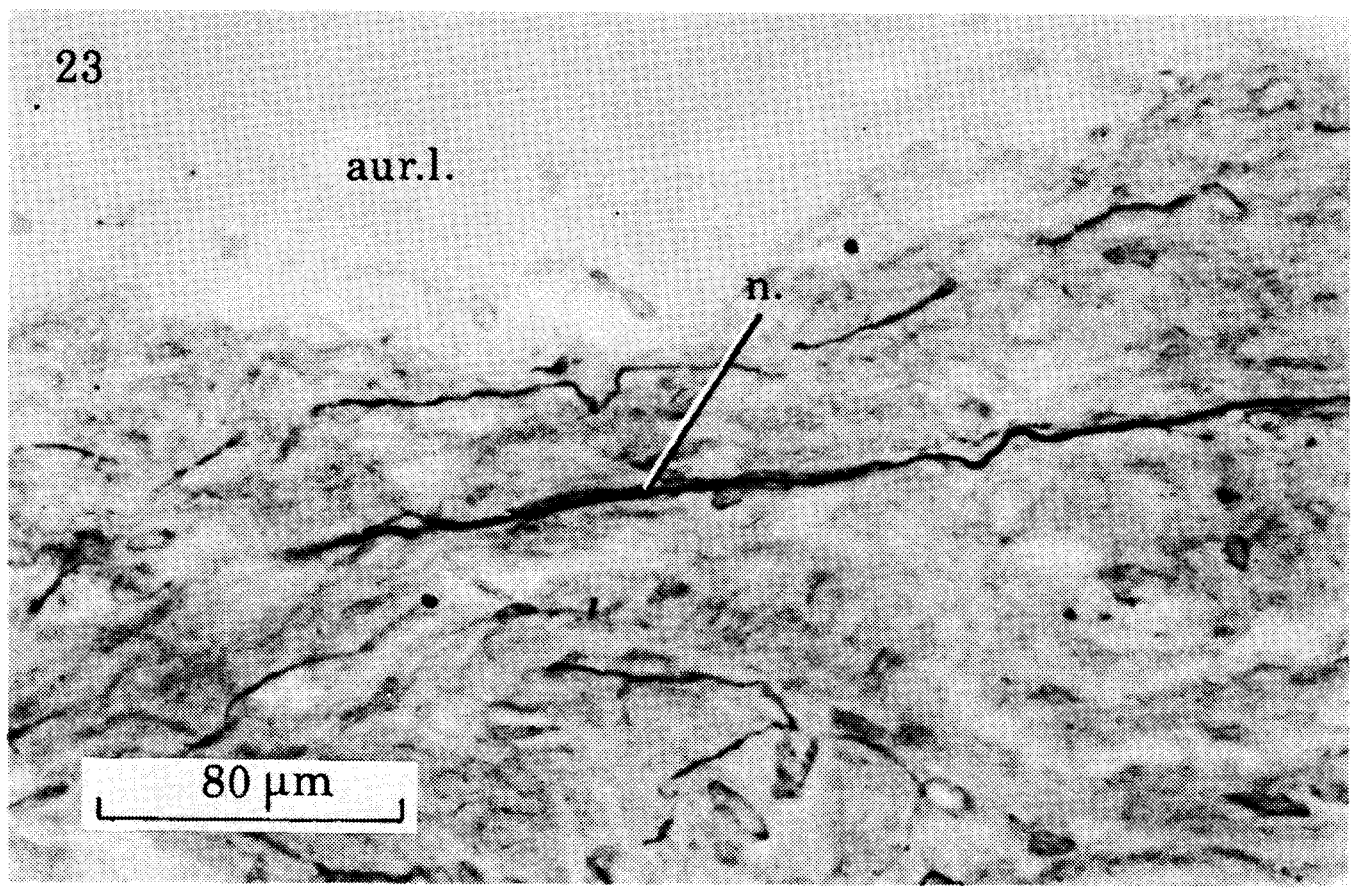

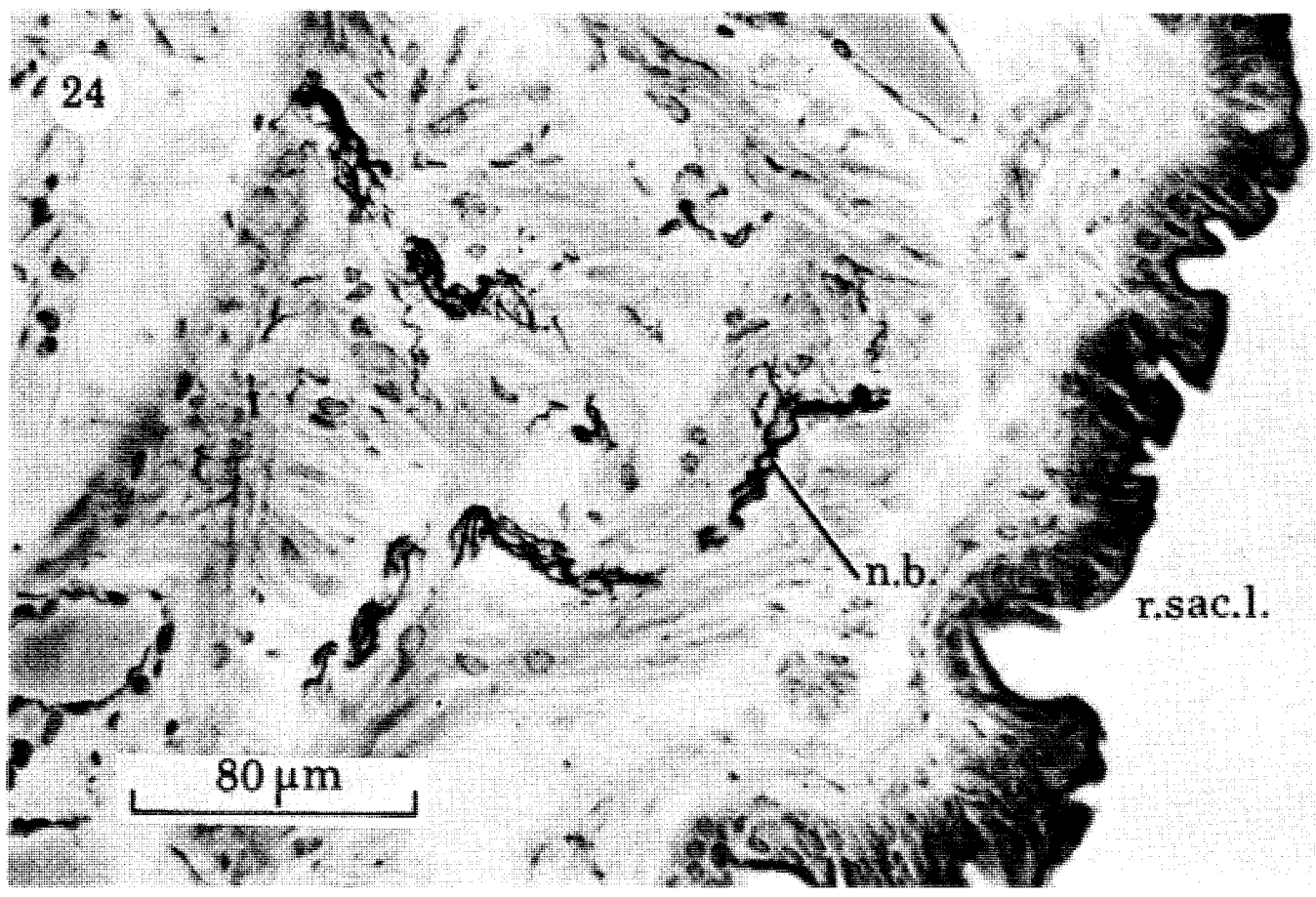

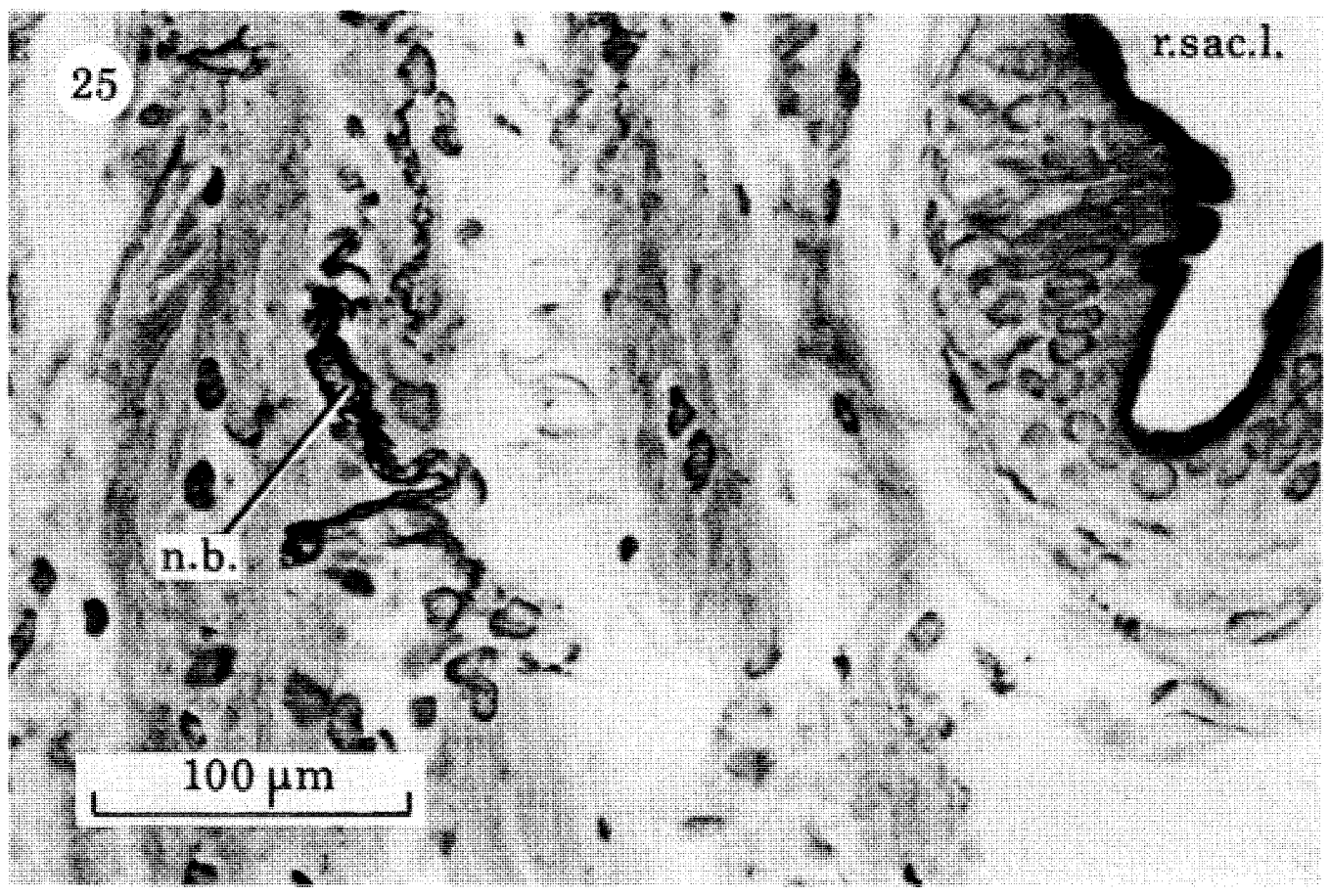

FIGURES 19–25. For description see page 505.

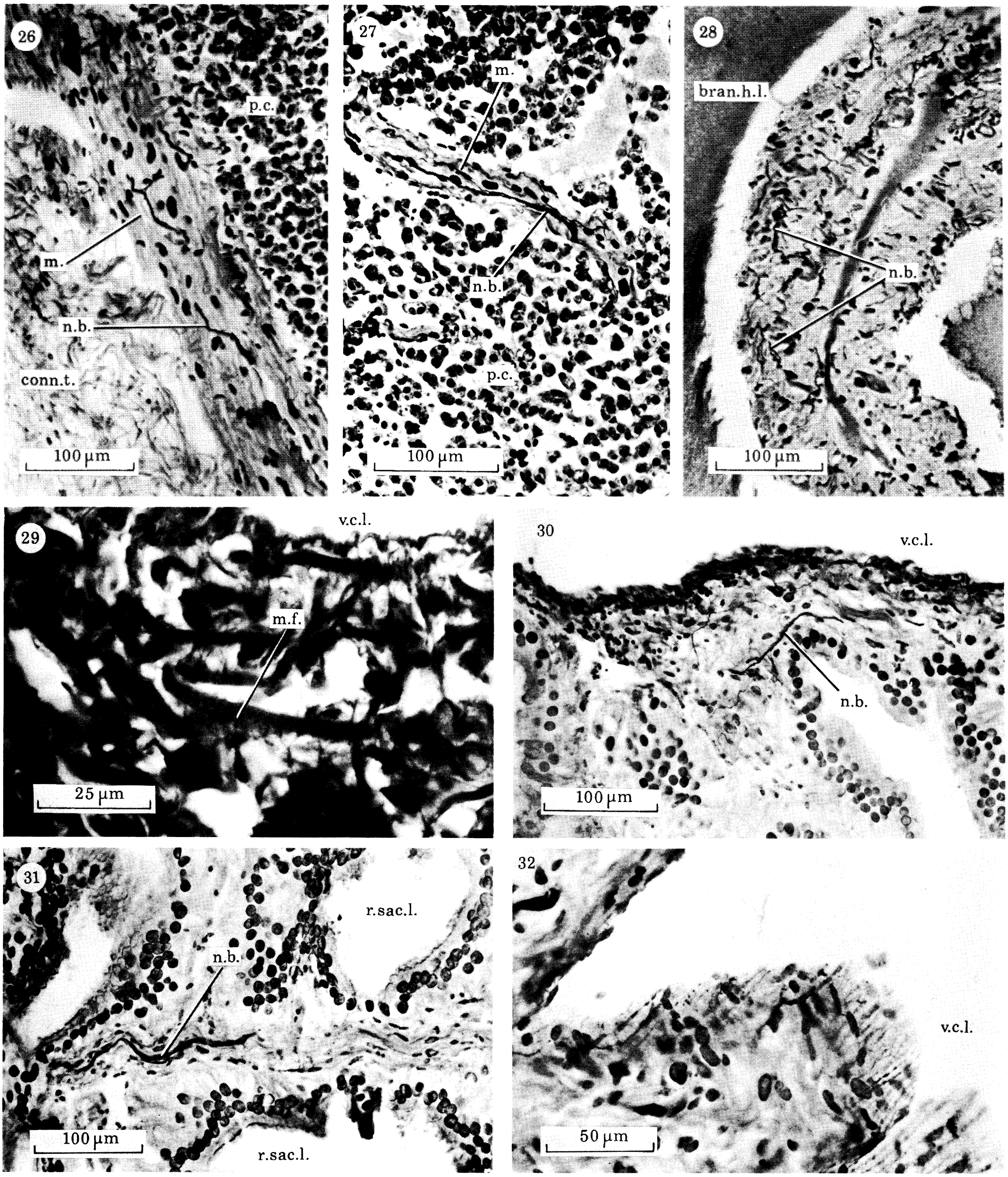

FIGURES 26–32. For description see opposite.

An auricular ganglion was also found on the left auriculo-ventricular nerve of a male *E. moschata* (figure 3*c*). Three specimens were examined, two males and a female. Subsequent histological examination confirmed the presence of nerve cell bodies. In this case the swelling of the nerve bundle caused by the cell bodies was so slight as to be barely visible in the methylene blue preparation, which raises the possibility that in the majority of preparations where the ganglion was not identified it may simply have been missed. In the three specimens of *O. vulgaris* examined, no auricular ganglion was found.

The cardiac ganglia (figures 5, 6) are remarkable features of the innervation to the octopod cardiac organs. Apart from the normal ganglionic structure, they each contain a pulsatile sac. The sac receives innervation from the ganglion and has its own vascular supply (probably originating from a branch of the branchial artery). Muscle fibres are present throughout the connective tissue matrix of the sac, and their contractions cause the ganglion to pulsate with the same frequency as the branchial hearts, although this action slightly precedes that of the hearts. In some freshly dissected preparations, contractions of the efferent branchial vessel, in the region where it joins the auricle, have been observed to occur in the intervals between successive contractions by the cardiac ganglion sac and branchial heart.

The branchial ganglia lie to the visceral side of the afferent branchial vessel at the base of the gill lamellae. Each ganglionic trunk is composed of a series of swellings due to concentrations of nerve cells sited at the base of each lamellar pair. In *E. cirrhosa* there are approximately 11 such swellings. The nerve bundle running between the lamellar stalks also has nerve cell bodies

---

Description of plate 3

Figure 19. Transverse section of the auricle, showing the two muscle layers separated by a thick connective tissue layer, through which runs the branchial artery, and the main auricular and ventricular nerves. (Mallory's stain.)

Figure 20. Transverse section of the muscle in the inner layer of the auricle, showing the presence of a large nerve bundle.

Figure 21. Transverse section of the muscle in the outer layer of the auricle, showing a large nerve bundle.

Figure 22. Single nerve fibres, with varicosities, innervating the muscle immediately at the edge of the auricular lumen.

Figure 23. An example of the general appearance of the nerve fibres in the inner muscle layer of the auricle.

Figures 24 and 25. Examples of the fibres innervating the muscle of the outer layer of the auricle. In comparison with the inner layer the innervation is more complex, with fibres tending to twist around each other.

Description of plate 4

Figure 26. Transverse section through the outer muscle sheath of the branchial heart, illustrating the general density of the innervation.

Figure 27. Longitudinal section through a muscular trabecula running through the packing tissue of the branchial heart. A small nerve bundle is present.

Figure 28. Transverse section of the valve leaflets between the lateral vena cava and branchial heart. An abundant innervation is evident.

Figure 29. A section cut through the muscle fibres bordering the lumen of the lateral vena cava. The fibres are disorganized, with striations weakly visible in some cases. (Mallory's stain.)

Figure 30. Transverse section through the lateral vena cava at the border of the lumen. Nerve fibres are evident in the muscle layer.

Figure 31. Transverse section through the renal appendages, showing the presence of innervation to this region.

Figure 32. A section cut obliquely to the lumen of the lateral vena cava, showing the ribbed appearance of the tissue lining the inner surface of the lumen.

incorporated along it. Each ganglionic swelling on the nerve trunk gives rise to two major nerve branches which innervate a pair of gill lamellae. Smaller branches innervate the gill retractor muscles and the branchial gland.

Small groups of nerve cell bodies are also present outside the peripheral ganglia listed above but within the outer connective tissue sheath of the main nerve trunks. In one specimen of *E. cirrhosa* a small group of nerve cell bodies, together with fine fibres resembling neuropil, was found within the right visceral nerve immediately distal to the fusiform ganglion (figures 8, 9, plate 1). A similar group of cell bodies was found within the branchial connective (figures 10, 11, plate 1) at the point where the branchial heart drained into the afferent branchial vessel. This group of cell bodies was shown to be present in the branchial connective of two branchial hearts, serially sectioned from different animals. They were not seen in the methylene blue preparations of the same specimens.

Fine innervation

This section applies only to *E. cirrhosa* and is based on silver-stained histological sections.

Ventricle

The ventricular muscle (myocardium) was moderately and uniformly innervated with small nerve bundles and single fibres as well as the occasional large nerve bundle (figure 12, plate 2). Within the myocardial layers the single nerve fibres, some of which showed varicosities along their length, tended to follow the orientation of the muscle fibre bundles (figure 13, plate 2). Although muscular, the valve leaflets at the auricular junctions were sparsely innervated. The valves at the aortic junctions were composed entirely of connective tissue and consequently were not innervated.

Within the ventricle two areas were found that appeared to have a specialized innervation. The first of these areas was associated with the coronary arterial supply, all sections of which showed that the arterial muscle was more abundantly innervated than the surrounding ventricular muscle. Figures 14 and 15 (plate 2) show sections cut longitudinally to a branch of a coronary artery. An extensive innervation was present (figure 16, plate 2), which arose from a small nerve bundle. A number of the fine fibres exhibited swellings along their length and at the endings. The second area of exceptional innervation was an extensive nerve plexus present in the muscle bordering the ventricular lumen (figure 17, plate 2).

In addition to the two areas of specialized innervation, groups of putative nerve cell bodies, with associated neuropil and nerve bundles, were observed (figure 18*a–c*, plate 2). These lay at the boundary of the ventricular myocardium and epicardium, near the junction with the auricle. These cells had a different staining characteristic from nerve cell bodies in the peripheral ganglia and cannot be definitely identified as neural in nature. No nerve cell bodies were seen within the myocardium.

Auricle

Each auricle forms a tube, composed of two layers of muscle fibre bundles separated by a thick layer of connective tissue (figure 19, plate 3). The outer muscle layer is common to the outer muscle of the lateral vena cava where the two organs run over each other. It is also continuous with the outer muscle layer of the ventricular epicardium. Within each of the layers of muscle, the fibres form a loose network of discrete muscle bundles, criss-crossing each other along the length of the auricle. The inner muscle layer runs into the ventricle at the region of the auriculo-ventricular valve.

The auricle is innervated by a number of nerve bundles arising mostly from the auricular and ventricular nerves, many of which run within the connective tissue between the muscle layers. Some relatively large bundles also run between the muscle bundles of the inner and outer muscle layers (figures 20, 21, plate 3). The inner muscle layer of the auricle is extensively innervated with nerve fibres running close to the auricular lumen, some of which show varicosities along their length (figure 22, plate 3). The nerve fibres innervating the inner muscle layer tend to run relatively straight (figure 23, plate 3) whereas those of the outer muscle layer interlace in a complex manner (figure 24, 25, plate 3) and in some cases appear to twist around muscle fibres.

Branchial hearts

The branchial heart has an unusual structure in which the greater part of the musculature is confined to an outer sheath 50–100 μm in thickness. Trabeculae arising from this sheath form a network of muscle bundles running within the cavity of the heart. This cavity is not entirely a vascular lumen as most of the space is occupied by a loose matrix of cells.

The outer muscle layer and trabeculae are innervated from the cardiac ganglion. The typical density of the innervation in the muscle layer is illustrated in figures 26 and 27, plate 4. The valve leaflets at the junction between the lateral vena cava and the branchial heart are similar in construction to the auriculo-ventricular valves, but more abundantly innervated from the cardiac ganglion (figure 28).

Lateral venae cavae

The muscle of the lateral venae cavae is located in a loosely organized layer, approximately 150–250 μm thick, adjacent to the lumen of the vessel. Muscle bundles can reach 75 μm in diameter and individual fibres sometimes show indistinct striations after general trichrome staining (figure 29, plate 4). The innervation to the lateral vena cava shows distinctly in the muscle surrounding the lumen of the vessel (figure 30, plate 4) as well as in the muscle of the renal appendages branching from it (figure 31, plate 4). In tissue bordering the lumen of the lateral vena cava, parallel ridges were observed after block silver staining (figure 32, plate 4). The nature of these ridges is obscure.

Discussion

The branching pattern of the visceral nerves to the circulatory organs shows an overall similarity in the three species of octopod studied; the main features of the innervation in *E. cirrhosa* are illustrated in figure 6. This composite picture shows the innervation to be more complex than in the accounts given by Chéron (1866), Isgrove (1909), Pfefferkorn (1915) and Young (1967). Several additional features, not reported by these authors, are included, which are of probable importance to a physiological study of coordination between the contractile organs.

The octopods investigated in this study all possess a comparable pattern of innervation to the auricles and ventricle, arising from or close to the fusiform ganglia. Separate auricular and ventricular nerves are present on each side of the animal. The distinction is, to some extent, nominal, because in some cases each nerve sends fibres to both the auricle and ventricle. In addition, they frequently run together before reaching the ventricle. Young (1967) observed that in *O. vulgaris* these nerves may be bound closely together, but in *Eledone* they are usually separate for most of their length. In *E. moschata* and *O. vulgaris* the ventricular nerve arises from the body of the fusiform ganglion whereas in *E. cirrhosa* it branches from the visceral nerve, distal to the fusiform ganglion. No functional variation is expected in relation to these differences.

Young (1967) remarked that in *O. vulgaris* the left and right ventricular nerves are joined by fine commissural strands over the ventral surface of the ventricle; such strands are also present in *Eledone*, although previously not described there. Another newly described feature of the ventricular nerves is that branches from them, at the level of the ventricle, innervate the lateral venae cavae. This observation may be significant in relation to the coordination of the rhythmic pulsations in the venae cavae with those of the ventricle. The innervation of the ventricle in the octopods by ventricular and auricular nerves from the fusiform ganglion is different from that in the decapods. In *Sepia officinalis* (Alexandrowicz 1960) and *Ommastrephes illecebrosa* (*Ilex illecebrosus*) (Carlson 1905), the ventricle is supplied by a single nerve bundle branching from the visceral commissure. These species have no equivalent of the fusiform ganglia.

The innervation of the decapod auricle is from nerve bundles arising from the cardiac ganglia (Alexandrowicz 1960; Carlson 1905). In *Sepia* there are approximately 50 nerve cell bodies lying close to the auricular nerve at the junction of the efferent branchial vessel and the auricle (Alexandrowicz 1960), but no such cells have been reported from the octopods. In *Loligo pealii*, Carlson (1905) described a small auricular ganglion on each of the auricular nerves from the cardiac ganglia. The auricular ganglion found by us in *Eledone* appears to be an analogous structure to that reported from *Loligo*, and constitutes an additional similarity between the octopod and decapod nervous system. In the octopods the equivalent of the nerve cells reported from the auricle of *Sepia* have possibly been incorporated into the fusiform and auricular ganglia, a trend that would be consistent with increased concentration in the nervous system. The presence of both the auricular ganglion and the putative nerve cell bodies in the ventricular epicardium are of relevance to *in vivo* physiological preparations involving the denervation of the cardiac organs (Wells 1980; Smith 1981), since one cannot any longer assume that by removing the fusiform ganglia the ventricle is deprived of all ganglionic influence.

The cardiac ganglia are present in both the octopods and the decapods, although, as far as is at present known, only in the octopods are they characterized by the pulsating intraganglionic body, for which a neurosecretory function has been tentatively suggested (Alexandrowicz 1963). The nerve branches arising from the cardiac ganglia are similar in all three species of octopod, and, although nerves running to the efferent branchial vessel were only seen in *Eledone*, it is likely that they are also present in *Octopus*. The results of *in vivo* nerve sectioning in *E. cirrhosa* imply that the innervation to the efferent branchial vessel is involved in maintaining the correct haemodynamic conditions for regular ventricular contraction (Smith 1981). These nerve branches may be responsible for coordinating the activity of the efferent branchial vessels with that of the branchial hearts.

Small groups of nerve cell bodies are found within the major nerve trunks of cephalopods. Alexandrowicz (1962) found groups of cells in the vasomotor nerves running to the posterior pallial vessels in *Sepia officinalis*. Young (1967) also reported nerve cells occurring irregularly along the rectal nerve of *O. vulgaris*. We have found two examples of nerve cell groups, one within the visceral nerve distal to the fusiform ganglion and the second within the branchial connective proximal to the first branchial ganglion. Ganglion cells are known to be common along the course of nerves in other molluscs (Bullock & Horridge 1965).

Nerve fibres in the ventricular muscle of *Eledone* often showed a series of swellings or varicosities along their length. A similar appearance to the nerves of the salivary duct in *Octopus* has been interpreted as evidence of neurosecretory activity (Arluison & Ducros 1976), but it seems more probable that the swellings that we have observed were due to the effects of the staining procedure (Garven & Gairns 1952).

The neuroanatomy of the ventricle raises the possibility that specialized nerve reflex areas exist. Two such possible areas were found. The first is the complex innervation surrounding the coronary arteries, the organization of which bears some resemblance to the vertebrate cardiac baroreceptors, illustrated by Heymans & Neil (1958). The second is the nerve plexus around the ventricular lumen. Innervation here is distinctly more abundant than in the ventricular myocardium generally. By comparison with the vertebrate system these may represent sensory areas for the reflex control of ventricular volume output. It remains to be shown at what level of the nervous system such information could be integrated.

The degree to which the auricle was innervated is surprising in view of the supposed lack of contractility of this organ. Johansen & Martin (1962) could find no evidence from *in vivo* pressure recordings that the efferent branchial vessels or the auricles contributed to the active propulsion of blood. Contractions of the auricle have been recorded *in vitro* by Fry (1909) but they were not of the same frequency as those of the ventricle. The extensive innervation of the auricle suggests that its function may be more important to the physiology of the circulatory system than is currently accepted. For example, tonic control by the nervous system of the auricular muscle, setting the diameter of the auricle and regulating the flow of blood to the ventricle, would be an important factor in the control of ventricular volume output (Smith 1981). Differences between the innervation of the inner and outer muscle layers of the auricle remain unexplained. The nerve fibres of these respective regions also differ in the condensation reaction in tests for the presence of catecholamines; nerve fibres of the inner muscle layer show fluorescence, but not those of the outer muscle layer (Smith 1979).

The innervation of the branchial hearts is confined to the outer muscle and extends along each of the muscular trabeculae. No nerve fibres were seen to run among the loose cellular matrix packing the lumen of the heart. The organ is known to be dependent for its normal activity on the integrity of the cardiac ganglion from which its innervation arises (Smith 1982; Wells 1980). Alexandrowicz (1913) tentatively identified nerve cell bodies in the branchial heart of *Octopus* but none were seen during this study.

Our results have shown that the lateral venae cavae are richly innervated and capable of strong contractions in freshly dissected and perfused preparations (unpublished observation). The presence of a neural link between the ventricle and the lateral venae cavae through the ventricular nerve may help to explain how, after the visceral nerves between the fusiform and cardiac ganglia have been severed, the contractions of the branchial hearts remain in phase with each other and the ventricle (Wells 1980). Wells proposed that the synchrony between the two branchial hearts may be the result of their following a common event upstream. The contractions of the lateral venae cavae could be such an event, adopting the contractile frequency of the ventricle via this nervous link. This proposition receives some confirmation from *in vitro* studies on perfused preparations (Smith 1979). Such a model would imply that the contraction sequence is led by the ventricle, as was proposed by Ransom (1884), and not by the cardiac ganglia, as suggested by Wells (1980).

This work was financed by a research studentship from the Carnegie Trust for the Universities of Scotland (P.J.S.S.) and assisted by a research grant from the N.E.R.C. (P.R.B.). The authors would like to thank Mr H. Watt and Mrs B. Smith for their histological advice and assistance, Mr A. Lucas and Mr L. Lockey for their help with the photographic work and Mr T. Craig for procuring the octopuses. The authors are also grateful to the Director and staff of the Laboratoire Arago, Banyuls-sur-Mer, for their hospitality and the use of their facilities. We wish to thank Professor Wynne-Edwards, F.R.S., for his critical reading of this paper and helpful comments.

REFERENCES

Alexandrowicz, J. S. 1913 Zur Kenntnis des sympathetischen Nervensystems einiger Wirbellosen. *Z. allg. Physiol.* **14**, 358–376.

Alexandrowicz, J. S. 1960 Innervation of the hearts of *Sepia officinalis*. *Acta zool., Stockh.* **41**, 65–100.

Alexandrowicz, J. S. 1962 An accessory organ of the circulatory system in *Sepia* and *Loligo*. *J. mar. biol. Ass. U.K.* **42**, 405–418.

Alexandrowicz, J. S. 1963 A pulsating ganglion in the Octopoda. *Proc. R. Soc. Lond.* B **157**, 562–573.

Alexandrowicz, J. S. 1964 The neurosecretory system of the vena cava in the Cephalopoda. I. *Eledone cirrosa*. *J. mar. biol. Ass. U.K.* **44**, 111–132.

Alexandrowicz, J. S. 1965 The neurosecretory system of the vena cava in the Cephalopoda. II. *Sepia officinalis* and *Octopus vulgaris*. *J. mar. biol. Ass. U.K.* **45**, 209–228.

Arluison, M. & Ducros, C. 1976 Localization of monoamine nerve fibres by formaldehyde fluorescence histochemistry in the posterior salivary duct and gland of *Octopus vulgaris*. *Tiss. Cell* **8**, 61–72.

Bullock, T. H. & Horridge, G. A. 1965 *Structure and function in the nervous systems of invertebrates*, vol. 2. San Francisco and London: W. H. Freeman & Co.

Carlson, A. J. 1905 Comparative physiology of the invertebrate heart. I. The innervation of the heart. *Biol. Bull. mar. biol. Lab., Woods Hole* **8**, 123–168.

Chéron, J. 1866 Recherches pour servir à l'histoire du système nerveaux des Céphalopodes. dibranchiaux. *Annls Sci. nat.* B **5**(5), 5–122.

Fry, H. J. B. 1909 The influence of the visceral nerves on the heart of cephalopods. *J. Physiol., Lond.* **39**, 184–206.

Garven, H. S. D. & Gairns, F. W. 1952 The silver diamine ion staining of peripheral nerve elements and the interpretation of the results; with a modification of the Bielschowsky–Gros method of frozen sections. *Q. Jl exp. Physiol.* **37**, 131–142.

Heymans, C. & Neil, E. 1958 *Reflexogenic areas of the cardiovascular system*. London: Churchill.

Isgrove, A. 1909 *Eledone*. *L.M.B.C. Mem. typ. Br. mar. Pl. Anim.* no. 18.

Johansen, K. & Martin, A. W. 1962 Circulation in the cephalopod, *Octopus dofleini*. *Comp. Biochem. Physiol.* **5**, 161–176.

Kuwasawa, K., Neal, H. & Hill, R. B. 1975 Afferent pathways in the innervation of a prosobranch gastropod *Busycon canaliculatum* L. *J. comp. Physiol.* **96**, 73–83.

Mislin, H. 1950 Nachweis einer reflektoischen Regulation des peripheren Kreislaufs bei den Cephalopoden. *Experientia* **6**, 467–468.

Packard, A. 1972 Cephalopods and fish: the limits of convergence. *Biol. Rev.* **47**, 241–307.

Pantin, C. F. A. 1964 *Notes on microscopical techniques for zoologists*. Cambridge University Press.

Pfefferkorn, A. 1915 Das Nervensystem der Octopoden. *Z. wiss. Zool.* **114**, 425–531.

Ransom, W. B. 1884 On the cardiac rhythm of invertebrates. *J. Physiol., Lond.* **5**, 261–341.

Smith, P. J. S. 1979 Studies on the circulatory organs of the octopus, *Eledone cirrhosa* (Lam.). Ph.D. thesis, University of Aberdeen.

Smith, P. J. S. 1981 The role of venous pressure in the regulation of output from the heart of the octopus, *Eledone cirrhosa* (Lam.). *J. exp. Biol.* **93**, 243–255.

Smith, P. J. S. 1982 The contribution of the branchial heart to the accessory branchial pump in the Octopoda. *J. exp. Biol.* **98**, 229–237.

S-Rozsa, K. & Salanki, J. 1973 Single neuron responses to tactile stimulation of the heart in the snail, *Helix pomatia* L. *J. comp. Physiol.* **84**, 267–279.

Stephens, P. S. 1971 Histological methods. In *The anatomy of the nervous system of Octopus vulgaris* (ed. J. Z. Young), pp. 646–649. Oxford: Clarendon Press.

Wells, M. J. 1979 The heartbeat of *Octopus vulgaris*. *J. exp. Biol.* **78**, 87–104.

Wells, M. J. 1980 Nervous control of heartbeat in octopus. *J. exp. Biol.* **85**, 111–123.

Wells, M. J. & Mangold, K. 1980 The effects of extracts from neurosecretory cells in the anterior vena cava and pharyngo-ophthalmic vein upon the hearts of intact free moving octopuses. *J. exp. Biol.* **84**, 319–334.

Young, J. Z. 1967 The visceral nerves of *Octopus*. *Phil. Trans. R. Soc. Lond.* B **253**, 309–321.

Young, J. Z. 1971 *The anatomy of the nervous system of Octopus vulgaris*. Oxford: Clarendon Press.

Young, J. Z. 1972 The organisation of a cephalopod ganglion. *Phil. Trans. R. Soc. Lond.* B **263**, 409–429.

Abbreviations used in the figures

a.b.v.	afferent branchial vessel
art.	artery
aur.	auricle
aur.g.	auricular ganglion
aur.l.	lumen of the auricle
aur.n.	auricular nerve
aur.ventr.n.	auriculo-ventricular nerve
a.v.c.	anterior vena cava
bran.	gill (ctenidium)
bran.art.	branchial artery
bran.conn.	branchial connective
bran.gl.	branchial gland
bran.gl.v.	branchial gland vein
bran.h.	branchial heart
bran.h.l.	lumen of the branchial heart
bran.v.	branchial vein
card.g.	cardiac ganglion
c.b.	cell body
comm.	commissural strands
conn.t.	connective tissue
cor.art.	coronary artery
d.aorta	dorsal aorta
e.b.v.	efferent branchial vessel
epi.	ventricular epicardium
fus.g.	fusiform ganglion
inner m.	inner muscle layer of the auricle
l.v.c.	lateral vena cava
l.v.c.n.	nerves to the lateral venae cavae
m.	muscle
m.f.	muscle fibre
n.	nerve
n.b.	nerve bundle
neur.	neuropil
n.pass	nerve fibres *en passant*
outer m.	outer muscle layer of the auricle
pal.ve.	pallial vein
p.c.	packing cells encapsulated by the muscle of the branchial heart
r.app.	renal appendages
r.sac l.	lumen of the renal sac
v.c.l.	lumen of the lateral venae cavae
ve.	vein
ventr.	ventricle
ventr.l.	lumen of the ventricle
ventr.myo.	ventricular myocardium
ventr.n.	ventricular nerve
vis.n.	visceral nerve

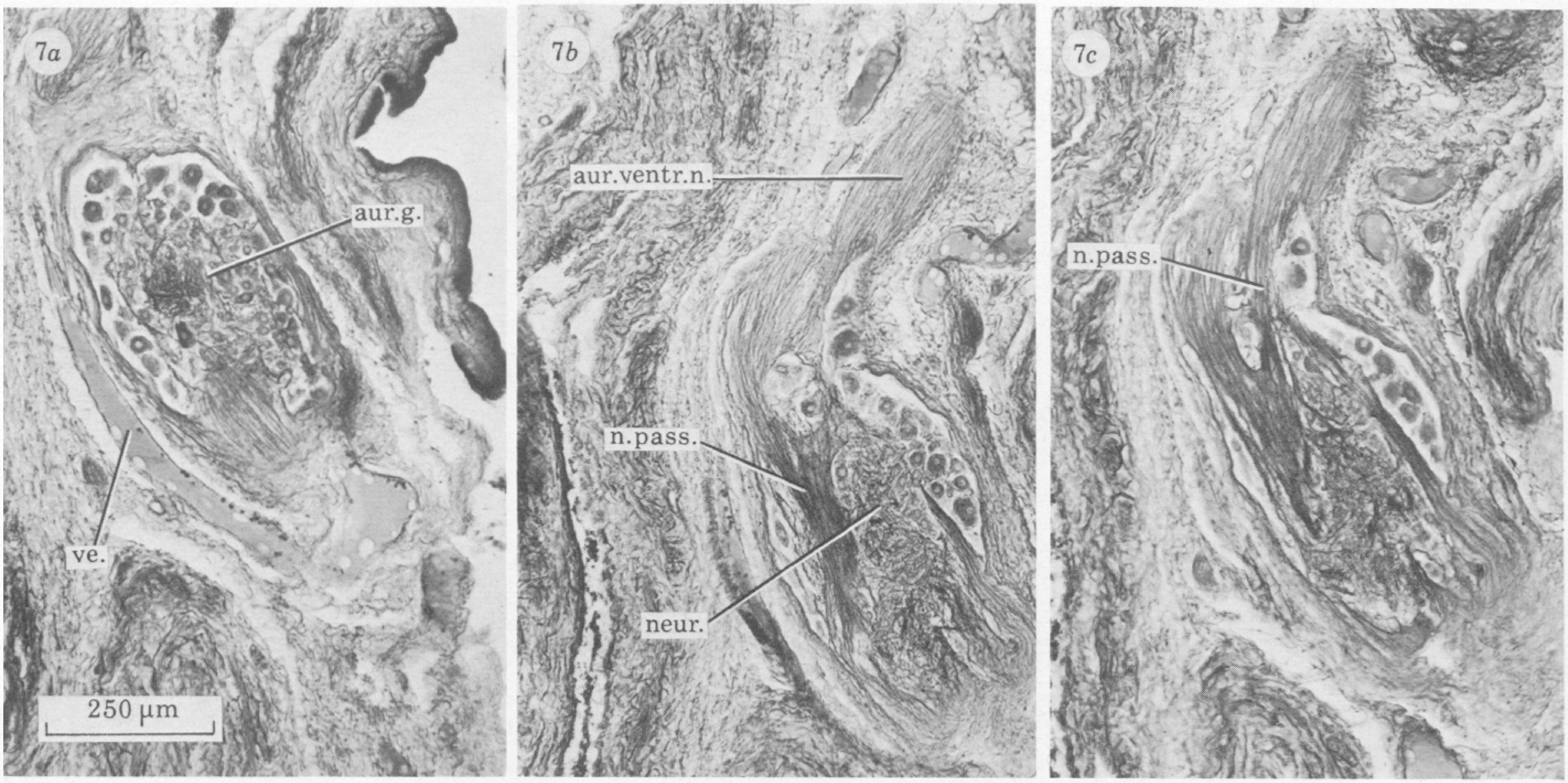

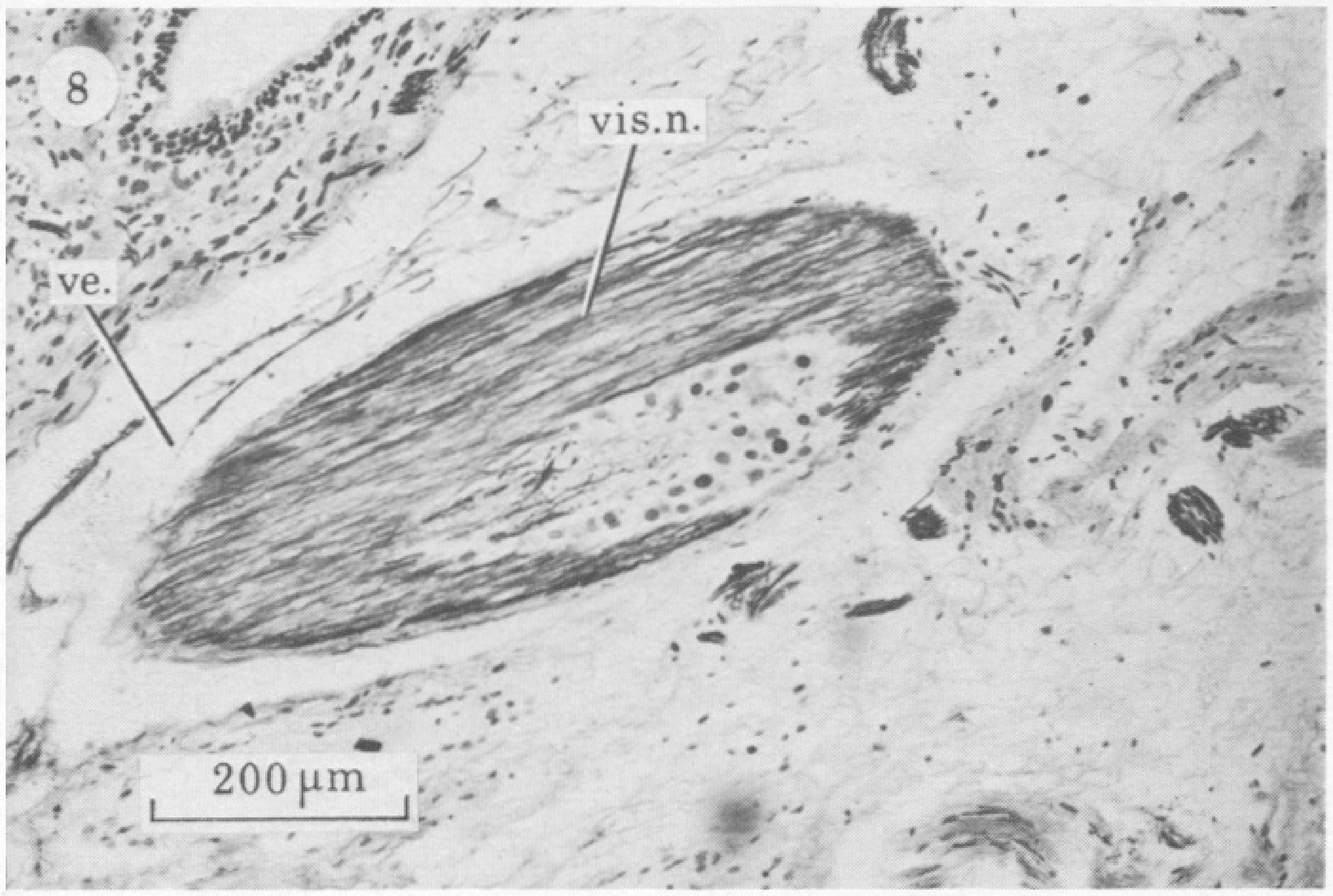

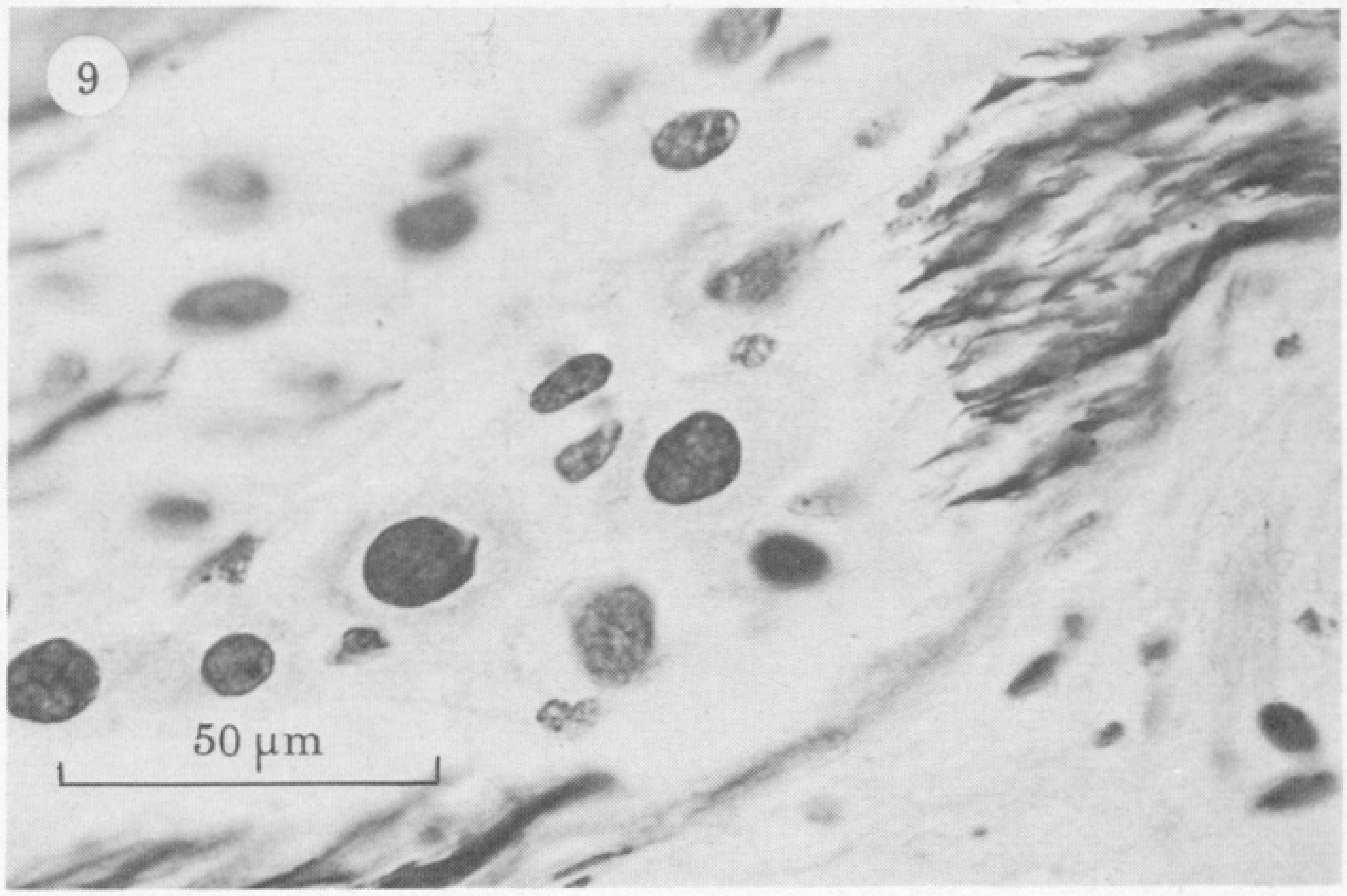

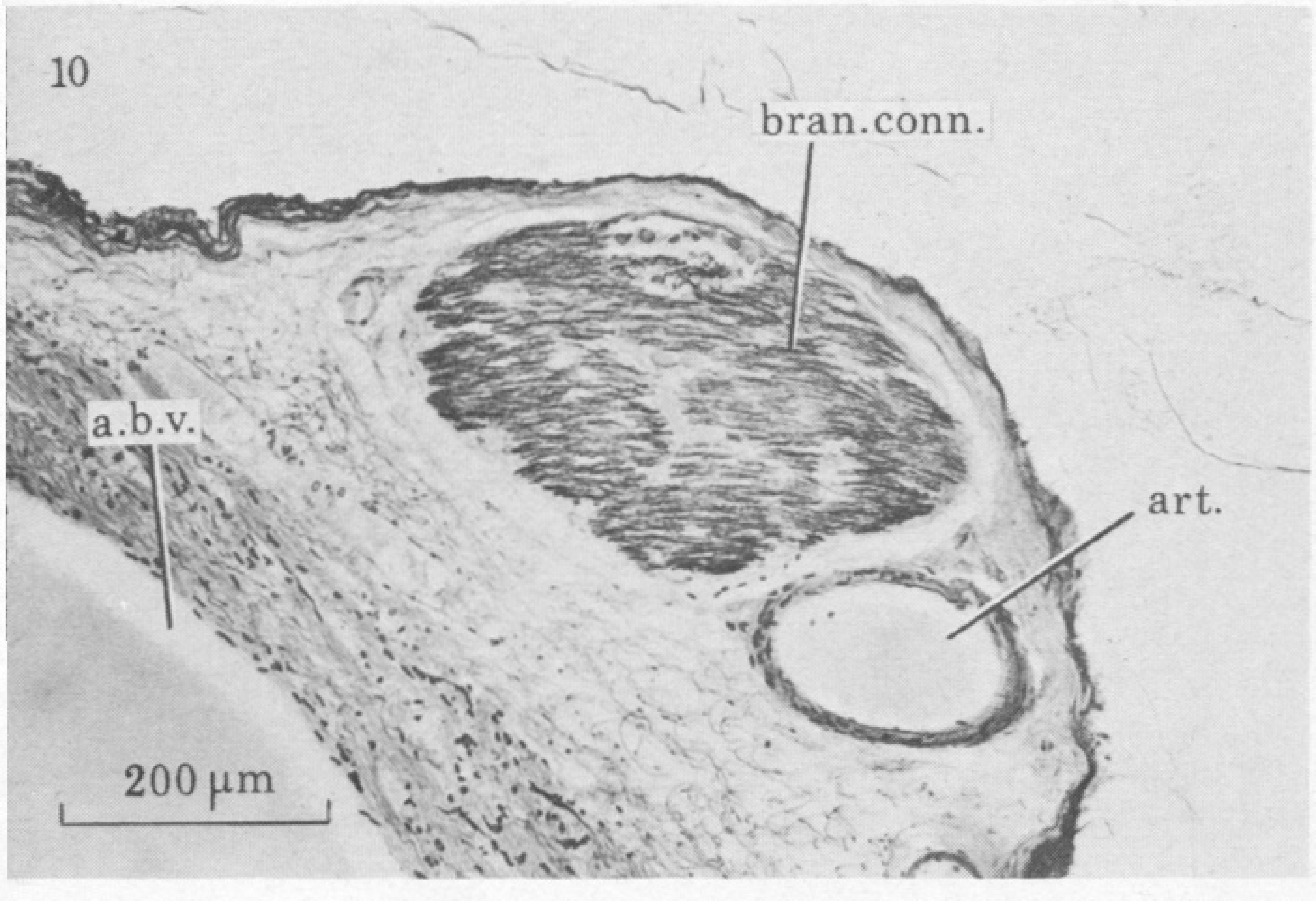

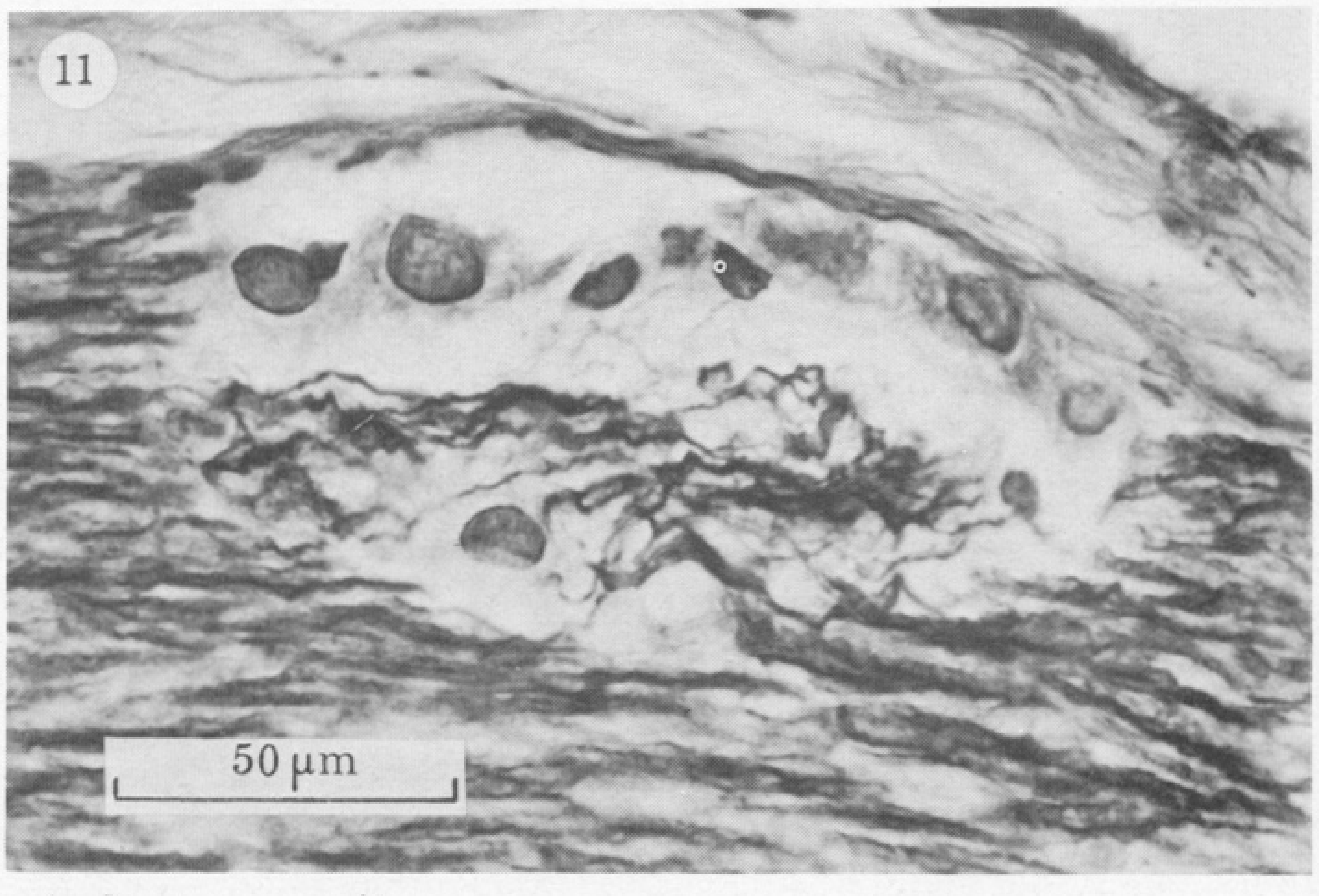

FIGURES 7–11. For description see opposite.

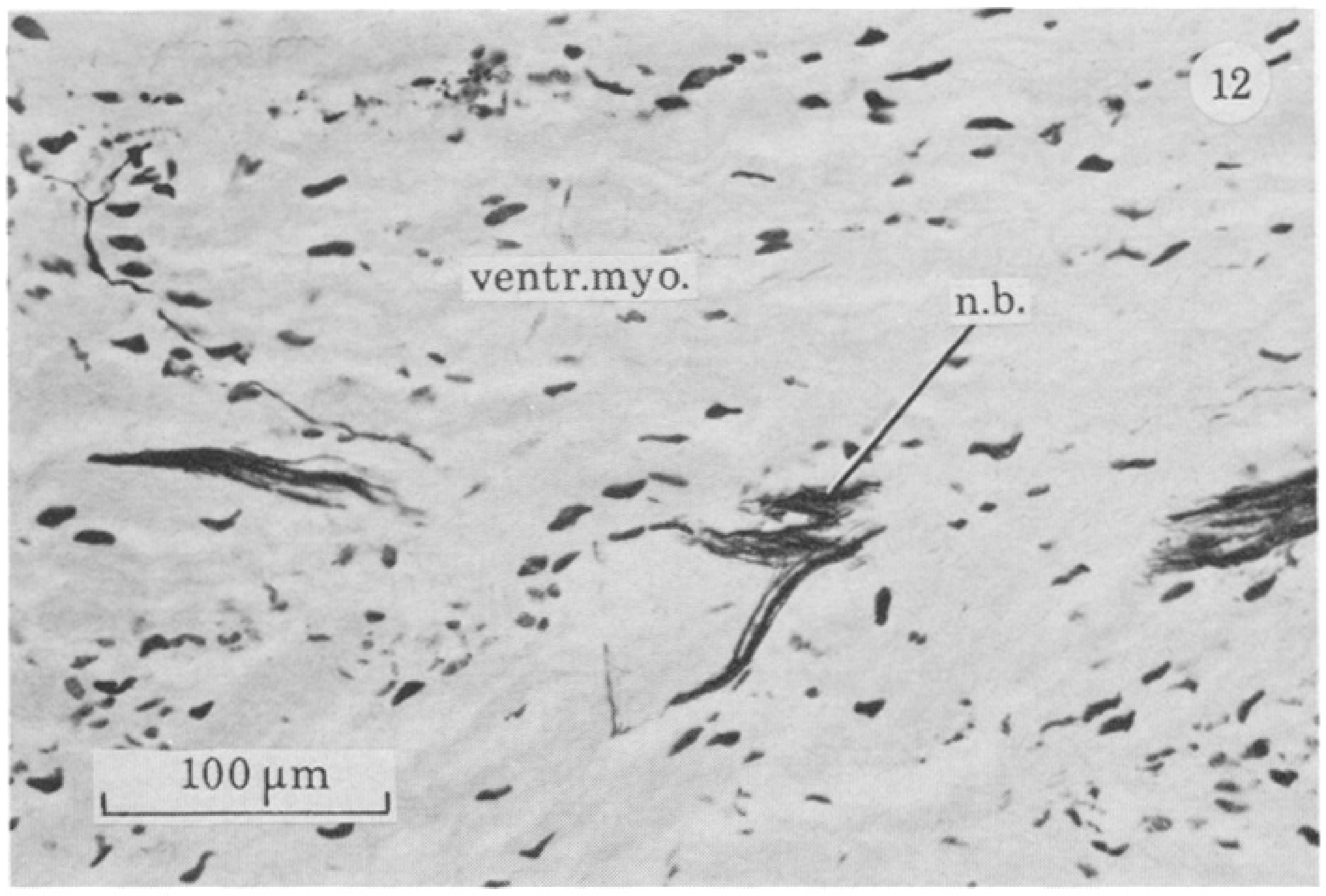



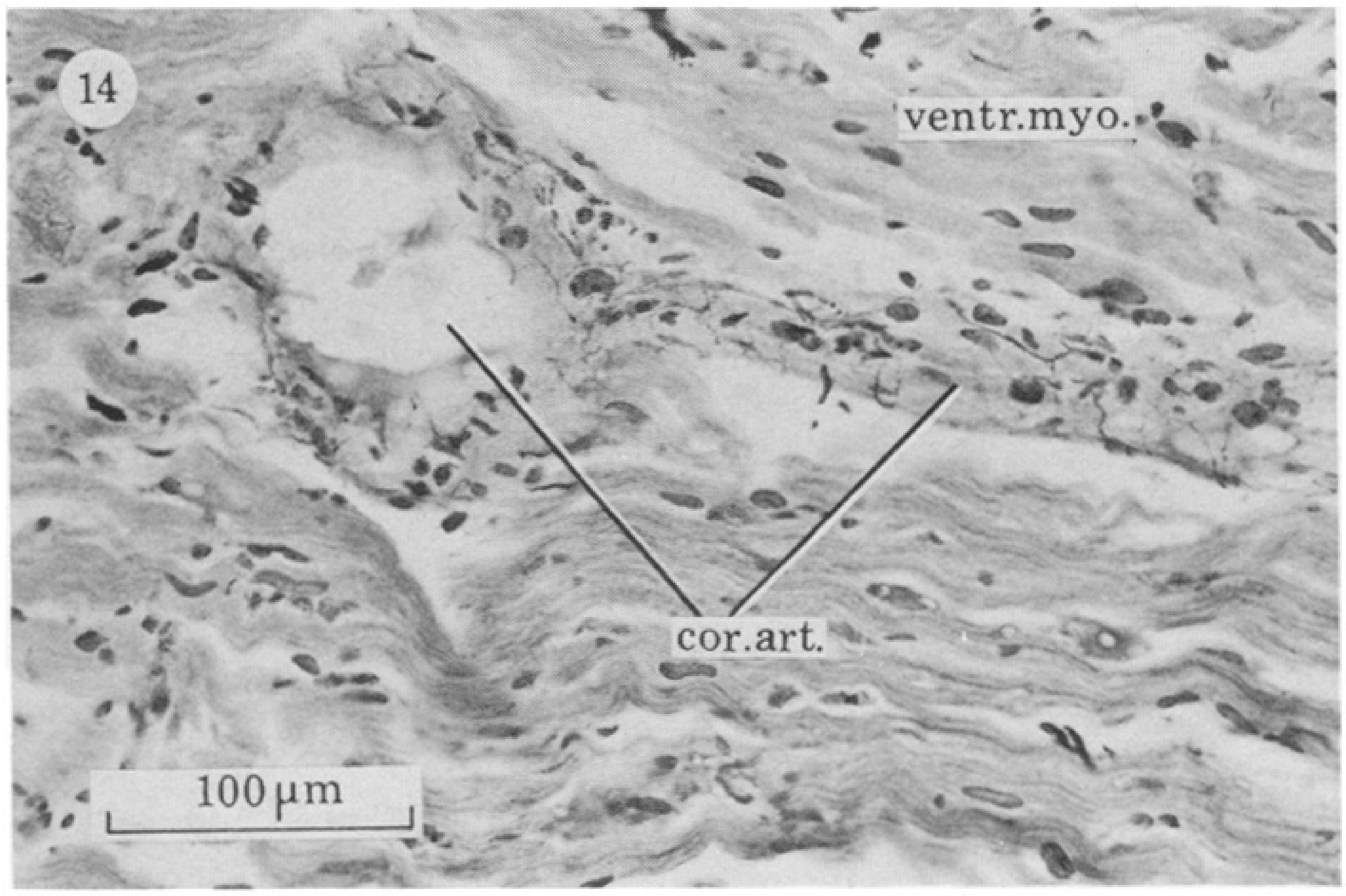

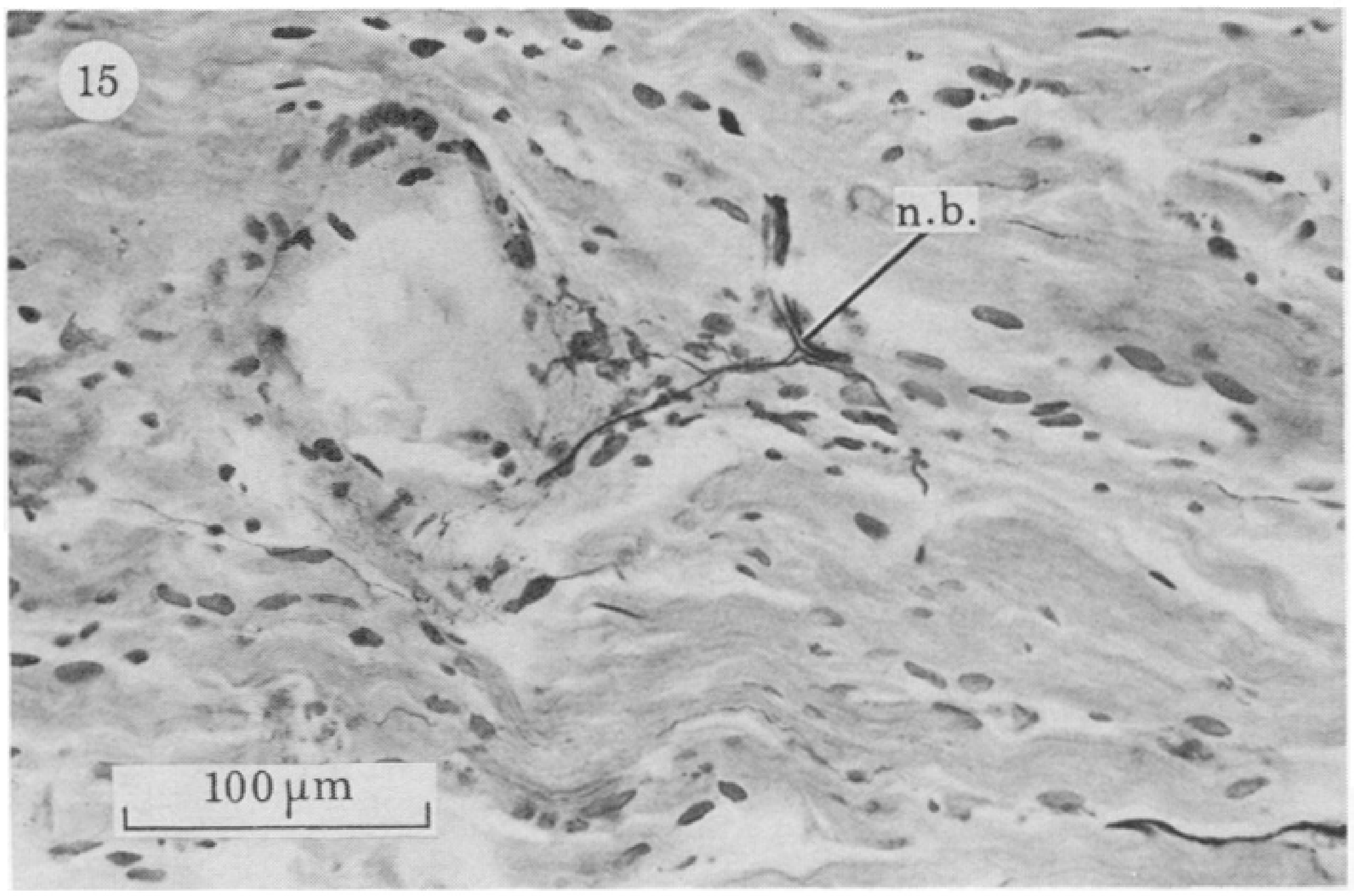

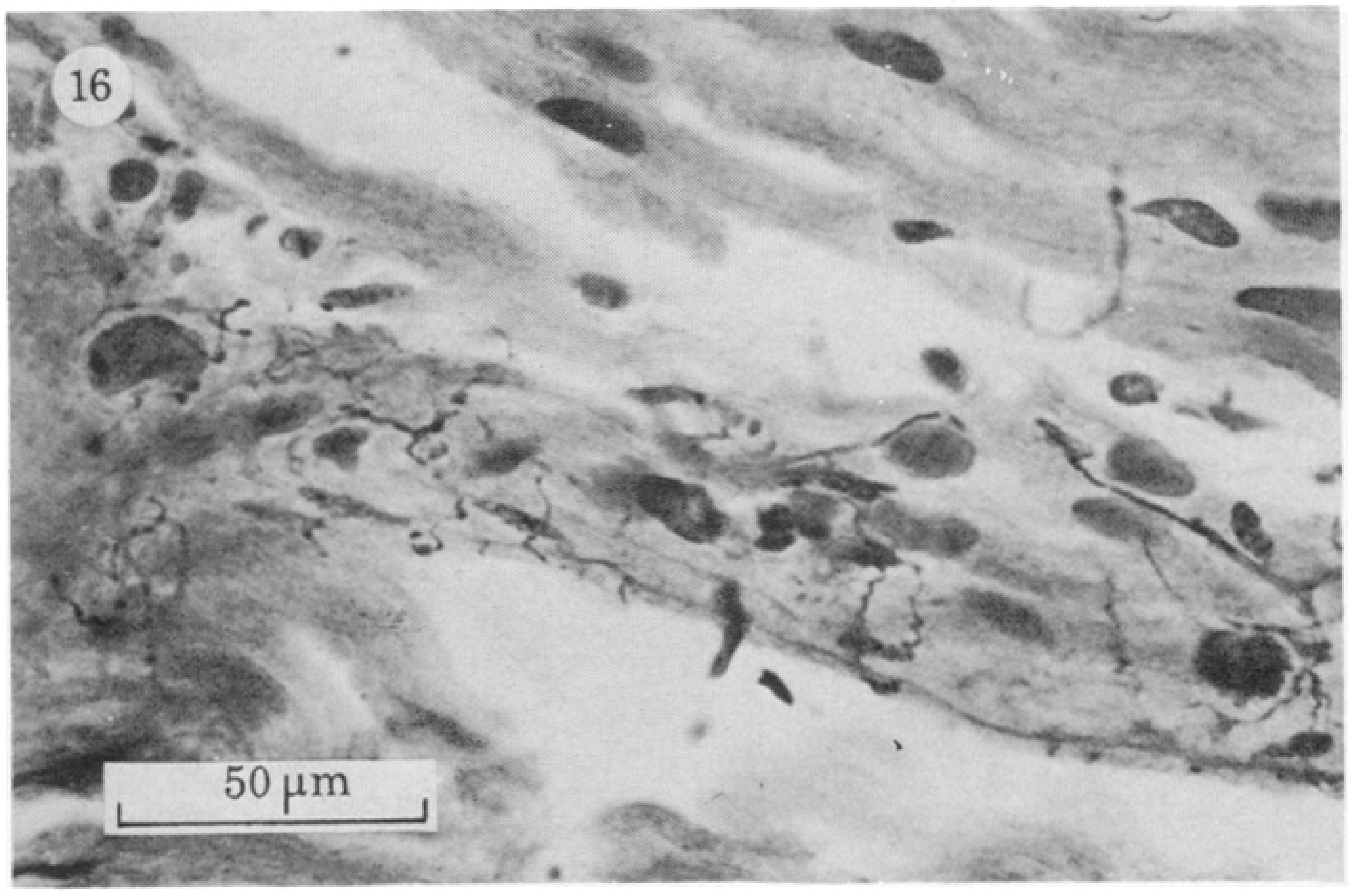

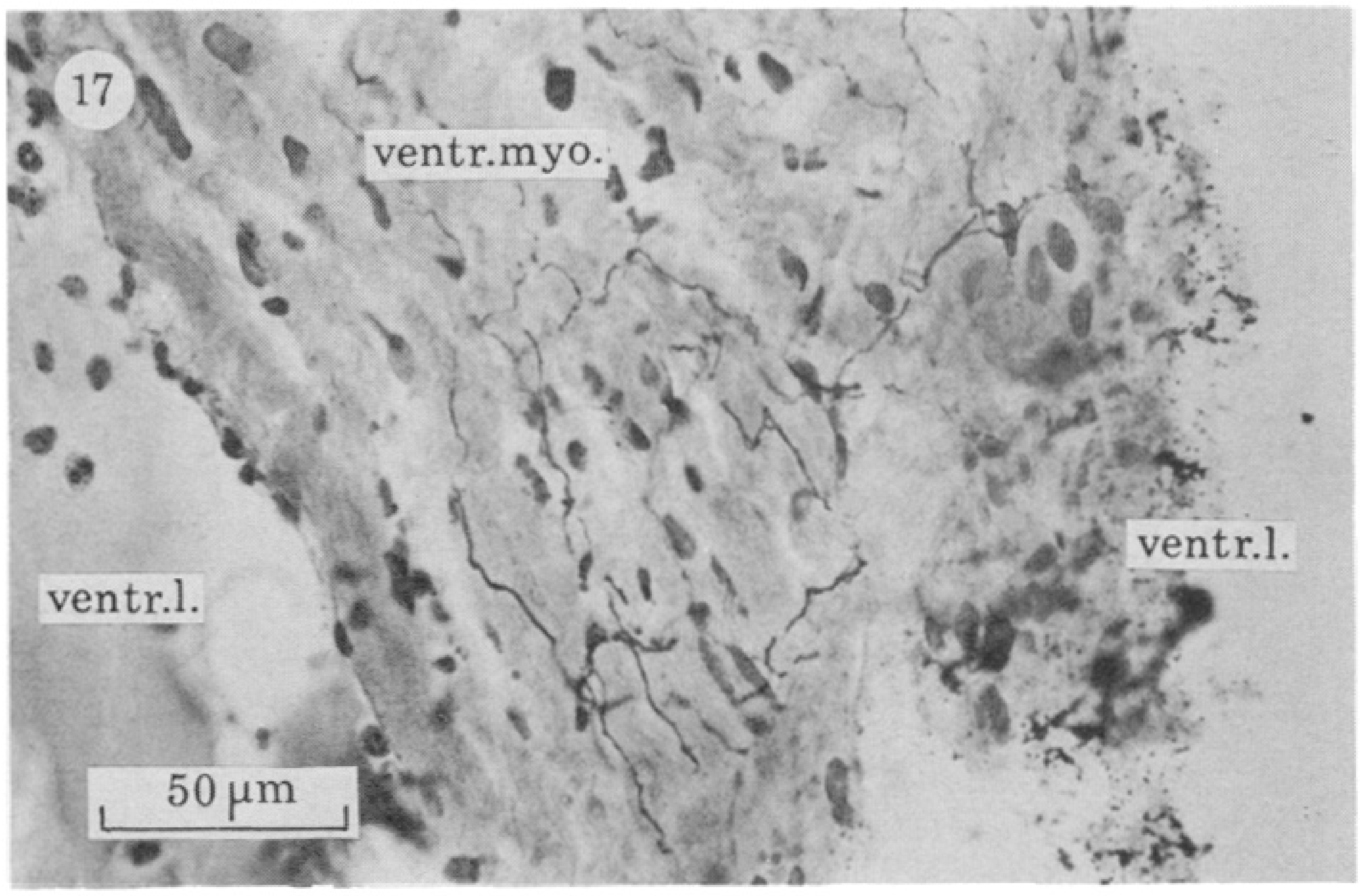

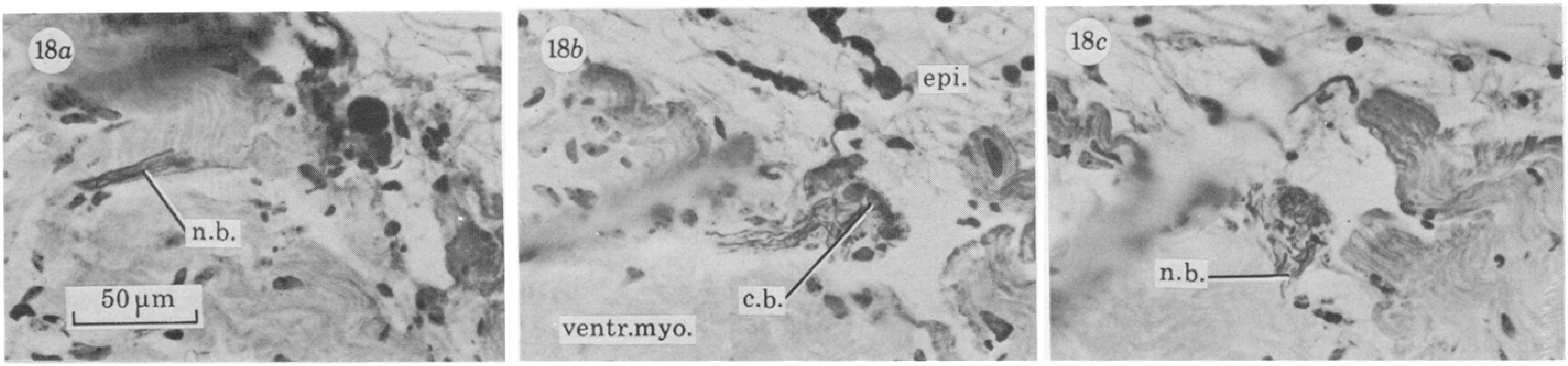

FIGURES 12–18. For description see page 504.

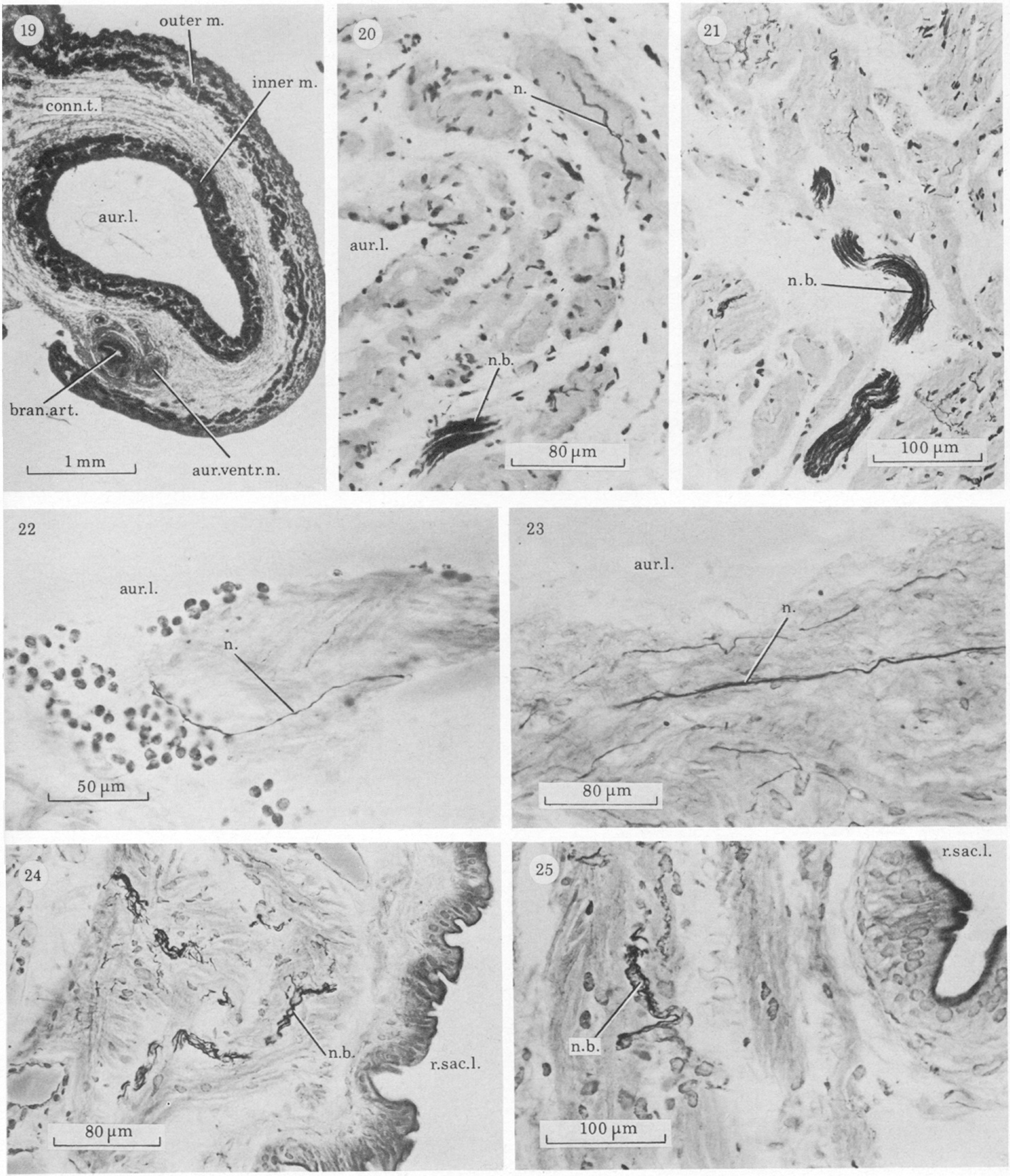

Figures 19–25. For description see page 505.

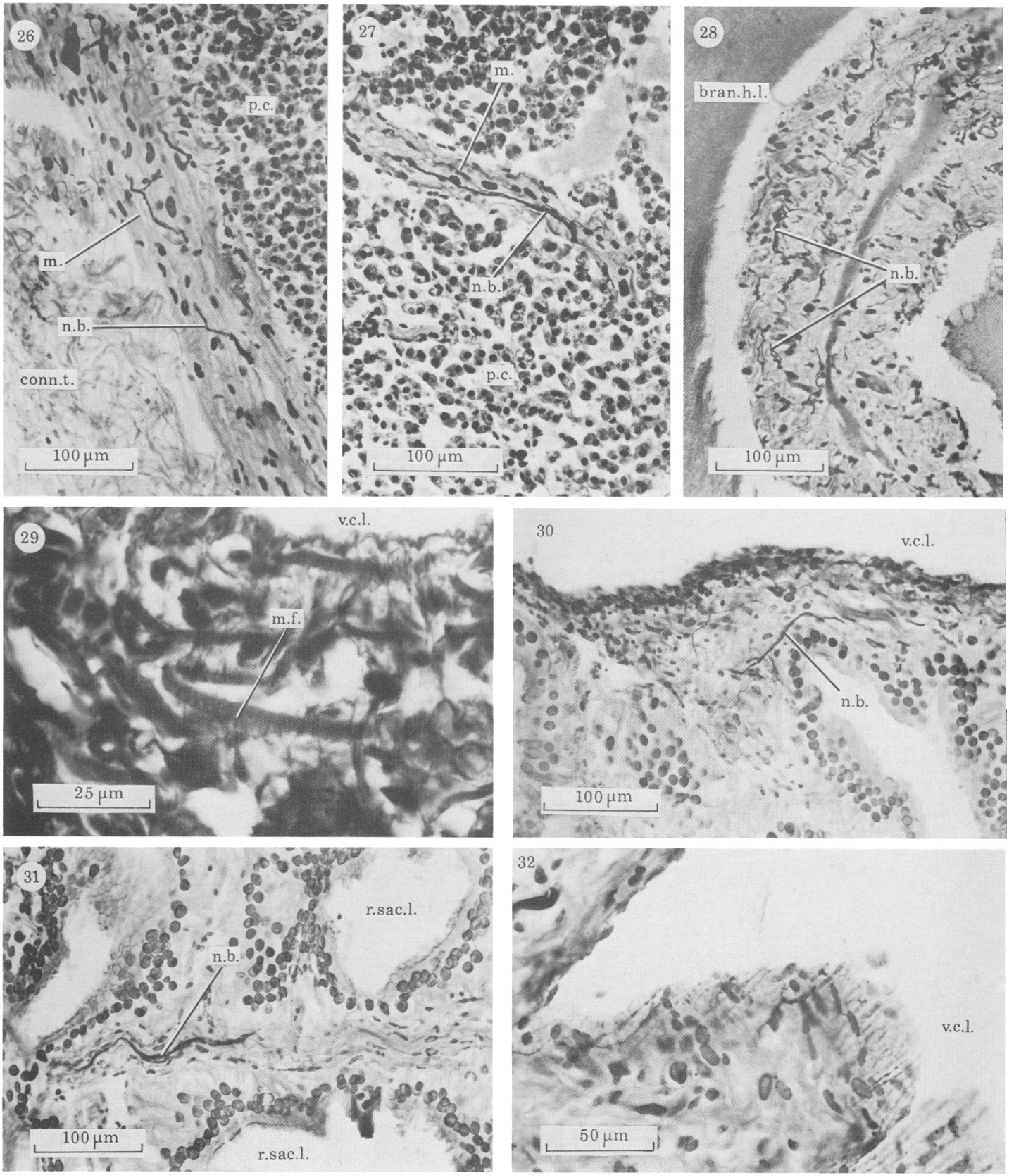

FIGURES 26–32. For description see opposite.